

See discussions, stats, and author profiles for this publication at: <https://www.researchgate.net/publication/256492155>

Correlative analysis of CinteC p16 and detection of Hpv dna by pCr in Cervical abnormalities

Article in *The Journal of medical laboratory technology* · January 2011

READS

60

3 authors, including:



[CD Izaaks](#)

Polytechnic of Namibia

4 PUBLICATIONS 6 CITATIONS

[SEE PROFILE](#)



[Sehaam Khan](#)

Cape Peninsula University of Technology

26 PUBLICATIONS 161 CITATIONS

[SEE PROFILE](#)

Peer reviewed ORIGINAL ARTICLE

CORRELATIVE ANALYSIS OF CINTEC P16 AND DETECTION OF HPV DNA BY PCR IN CERVICAL ABNORMALITIES

CD Izaaks¹ (MTech) | EJ Truter² (PhD) | S Khan² (PhD)¹ Department of Biomedical Sciences, School of Health and Applied Sciences, Polytechnic of Namibia, Windhoek, Namibia² Department of Biomedical Sciences, Faculty of Health and Wellness Sciences, Cape Peninsula University of Technology (CPUT), Cape Town, South Africa

Corresponding author: S Khan | tel: (+2721) 959 6911 | fax: (+2721) 959 6902 | email: KhanS@cput.ac.za

Abstract

Background The prognostic value of cervical aberrancies cannot be adequately determined by the Pap smear alone. Detection of HPV DNA by polymerase chain reaction (PCR) improves the diagnostic sensitivity however, it lacks sufficient specificity. Biomarkers that demonstrate the power to identify progressive cervical lesions may enhance the accuracy of Pap smear screening. The objective of this study is to investigate the relationship between P16 expression and HPV DNA in cervical smears, and the diagnostic accuracy of these assays.

Methods Following p16^{INK4A} immunocytochemical analysis, we subjected 187 abnormally classified cervical smears to HPV detection by PCR. The correlation between HPV DNA and p16^{INK4A}, stratified by cervical cytology, were examined.

Results Both assays produced a high sensitivity for the detection of HPV by p16^{INK4A} 96.4% (95% CI, 86.2-99.4), and GP5+/6+ PCR 98.11% (95% CI, 88.6-99.9) in higher grade squamous intraepithelial lesions (HSILs), respectively. The specificity for P16 expression in conjunction with conventional cytology was significant in LSIL 85.7% (66.4-95.3) and ASC-US 50% (20.1-79.9) while the sensitivity peaked when conventional cytology was supplemented by p16^{INK4A} in LSIL 90.12% (81-95.3) and ASC-US 71.4% (51.1-86) lesions.

Conclusion The p16^{INK4A} assay show potential to overcome the present restrictions often encountered during cervical cancer screening.

Keywords

p16^{INK4A}, human papilloma virus, cervical cancer

INTRODUCTION

Since the introduction of the Papanicolaou (Pap smear) cytological screening in the early 1940s, there has been a considerable reduction of up to 80% in the incidence and mortality from cervical cancer^[1]. However, it has been reported that the diagnostic accuracy of the Pap smear is impeded by a high interobserver reproducibility and low clinical sensitivity and specificity that vary between 20%-30%^[2] and 5%-70%^[3], respectively. Even though liquid-based cytology (LBC) has led to enhanced diagnostics, cytological screening of the cervix depends on subjective morphologic methods that may be linked to sampling inaccuracies and interpretation bias.

Most high-risk human papilloma virus (HR-HPV) infections will regress spontaneously, whilst only a few will develop into precancerous lesions or invasive cancer. While low-risk HPV types are frequently associated with benign warty lesions that generally resolve spontaneously, constant infection with high-risk human papilloma virus (HR-HPV) (types 16, 18, 31, 33, 35, 39, 45, 51, 52, 56, 58, 59, 66, 68, perhaps others) is critical in cervical carcinogenesis^[4-5]. Moreover, HPV types 16 and 18 associated infections have a greater absolute risk of progression to cervical precancer and cancer than other HPV types^[6-8] and account for 70% of cervical cancers in the general population^[9-10]. In fact, HR-HPV (especially HPV types 16 and 18) can be detected in up to 25% of women without cervical lesions^[10]. In view of this, it is vital to recognize specific biomarkers that could predict clinically significant HR-HPV infections. Though

HR-HPV DNA testing is considered the most sensitive indicator of high-grade cervical lesions, and the combination of HPV testing and the Pap test have a sensitivity and negative predictive value of almost 100%^[11], it lacks sufficient specificity to conclusively diagnose clinically significant cervical disease. Furthermore, a single HPV DNA test, although it could confirm infection by the virus present in 99% of all cervical cancers^[12], does not discriminate between latent and chronic infection, it merely indicates a risk of cervical disease. The discrimination between the two types of infections is therefore fundamental as it is the persistent infection that predisposes to cervical disease progression and not the latent one^[13]. Novel biomarkers employed on cervical smears may improve the identification of women with ambiguous results that may require treatment.

When HR-HPV infects the cell, it leads to neoplastic progression via two viral oncoproteins, E6 and E7. The E6 oncoprotein forms a covalent chemical bond with the p53 tumour suppressor protein while the E7 oncoprotein binds to the retinoblastoma protein, pRb, with concomitant liberation of the transcription factor E2F. During normal cell differentiation, the cyclin-dependent kinase (CDK) inhibitor slows down the cell cycle through inactivation of CDKs, subsequently resulting in the addition of a phosphate group to the pRb. However, in its dephosphorylated state, pRb attaches to the E2F transcription factor and this pRb-E2F complex down-regulates the p16 gene. Since P16 expression is under a negative feedback control mechanism, diminished pRb production results in an elevated

expression of the P16 tumour suppressor protein.

The value of p16^{INK4A} as a surrogate marker of HR-HPV and CIN has been well established. In addition, the variability of the CIN diagnoses can be augmented with p16^{INK4A} immunostaining^[14] and cervical disease progression may be possible^[15]. In recent years, numerous studies have advocated the use of p16^{INK4A} in the detection of high grade lesions in cervical cytology^[16-19]. The present study was designed to evaluate: 1) the sensitivity and specificity of p16^{INK4A} as a marker for cervical aberrancies in the triage of cervical smears, 2) the relation between p16^{INK4A} immunocytochemistry and HPV by GP5+/6+ PCR targeting the E6/E7 region of HPV, and 3) the correlation between p16^{INK4A} cytology and HR-HPV types 16 and 18 detection by PCR, stratified by cervical cytology to elucidate their association with the aim of improving clinical evaluation and management.

We studied P16 expression in a prospective series of 187 cervical specimens, processed by the Papanicolaou staining method, obtained from patients with cytologically diagnosed cervical abnormalities. We applied a standardized immunocytochemical method followed by concurrent testing for the presence of HPV infection using PCR, after which type-specific PCR (HR-HPV types 16 and 18) was employed. Furthermore, we compared p16^{INK4A} findings with PCR data in the respective cervical categories.

MATERIAL AND METHODS

Specimen collection and Pap staining

The study subjects included 3839 women between the ages of 15-49 years attending public health care facilities for gynaecological screening. After written informed consent was received, an interviewed administered questionnaire centering on patient demographics, sexual and reproductive history and Pap smear screening history of participants was obtained. Papanicolaou staining was executed on all cervical smears, followed by microscopical assessment using the Bethesda system (TBS) of 1991 combined with the CIN classification. The respective cytological diagnoses were regrouped as negative for intraepithelial lesions or malignancies (NILMs), atypical squamous cells of undetermined significance (ASC-US), low-grade squamous intraepithelial lesions (LSILs), atypical squamous cells-cannot rule out HSIL (ASC-H) and high-grade squamous intraepithelial lesions (HSILs) using TBS of 2001^[20].

p16^{INK4A} immunocytochemical staining

Preceding antibody staining, abnormally classified cervical smears were decolorized and incubated in 50% ethanol for 10 min, air-dried for 5 seconds, and rinsed in wash buffer. Immunostaining was performed using the Cintec p16^{INK4A} cytology kit (Dako, Glostrup, Denmark), following the manufacturer's instruction. Fourteen cervical smears categorised as "NILM" were incorporated as negative controls. Following incubation by mouse anti p16^{INK4A}, visualization for cytology was optimised using a polymer visualisation reagent. Clearly demonstrated brown colorization of the cytoplasm and nucleus in abnormal cells was deemed as positive for immuno-expression.

HPV-PCR testing

Subsequent to immunostaining, cellular material on slides were gently scraped off with a sterile scalpel blade and collected into a sterile microcentrifuge tube constituting tissue lysis buffer. The High Pure PCR Template Preparation kit (Roche Diagnostics GmbH Mannheim, Germany) was used for DNA extraction.

GP5+/GP6+ consensus primers, which amplify a 150 basepairs (bp) fragment located in the L1 region of the HPV genome, were used to identify genital HPV infection^[21]. GP5+/GP6+ PCR positive samples were tested for the presence of HR-HPV types 16 and 18, positioned in the E7, 667-686 and 753-774 region of the HPV genome, respectively^[22]. Amplification of a 108 bp and 191 bp DNA fragment were regarded as the presence of HPV types 16 and 18, respectively.

Statistical analysis

All statistical analysis was conducted using SPSS 19.0 (IBM SPSS Statistics 19.0.0.1 for Windows Inc, Chicago, IL, USA). Pearson chi-square tests and Spearman's rank correlation analysis were used to analyze HR-HPV (types 16 and 18) infection and P16 expression. To investigate the diagnostic accuracy of HR-HPV types 16 and 18, p16^{INK4A}, and the combination of conventional cytology and p16^{INK4A}, the subjects were separated into their respective cytologic categories. Estimates for diagnostic sensitivity and specificity were computed from cross-tabulation of test results at 95% confidence intervals (CIs). The positive predictive values (PPV) and negative predictive values (NPV) were generated to determine the diagnostic accuracy of the p16^{INK4A} immunocytochemistry test. Concordances between the different tests were measured using Kappa statistics. Theoretically, kappa values of <0, 0 to 0.2, 0.21 to 0.4, 0.41 to 0.6, 0.61 to 0.8, 0.81 to 0.99, 1.0 suggest poor, slight, fair, moderate, substantial, almost perfect, and perfect agreement, respectively. The two-sided McNemar test was used to evaluate the disparity between results obtained with the PCR and p16^{INK4A} method. All statistical analyses were regarded as significant if $p < 0.05$.

RESULTS

Of the pool of 187 abnormally classified cervical smears, 113 (60.4%) expressed P16 immunoreactivity. These comprised of 50/96 (52.1%) cases with LSIL, 5/28 (17.9%) cases with ASC-US, 51/54 (94.4%) cases with HSIL, and 7/9 (77.8%) cases with ASC-H. The p16^{INK4A} results in relation to the cytology diagnoses are provided in Figure 1, demonstrating a direct relationship between P16 expression and severity of the lesion.

Five samples yielded inadequate DNA and were omitted for further testing. Infection with HPV types 16 and/or 18 were detected in 54 (31.4%) of 172 GP5+/6+ positive samples: 21 (12.2%) cases showed high-risk HPV type 16, 25 (14.5%) cases displayed high-risk HPV type 18, and the remaining eight (4.7%) cases showed dual infection with both subtypes. Seven (28%) of the ASC-US, 24 (27.6%) of the LSIL, two (22.2%) of the ASC-H, and 21 (41.2%) of the HSIL-classified lesions demonstrated the presence of high-risk virus subtypes 16 or 18 (Table 1).

Correlation between P16 expression and HPV infection stratified by cervical cytology

Table 2 demonstrates the results of P16 expression and HPV status with respect to the type of lesion. Of the 172 cases that were HPV-positive with GP5+/6+ PCR, 108 (59.3%) showed P16 expression. For the 52 cases of HSIL, p16^{INK4A} and HPV DNA by PCR yielded almost identical results with 48 (92.3%) specimens being positive and three negative for p16^{INK4A} and 51 (98.1%) positive and one negative for HPV DNA by PCR. One specimen which was p16^{INK4A} negative was analogous to the one that was negative for HPV detection using PCR. Moreover, four (14.8%) of the 27 ASC-US and 49 (52.1%) of the 94 LSIL cases were positive for both assays. Nine cases that were HPV-negative were negative for P16 protein: 2/27 ASC-US, 7/94 LSIL

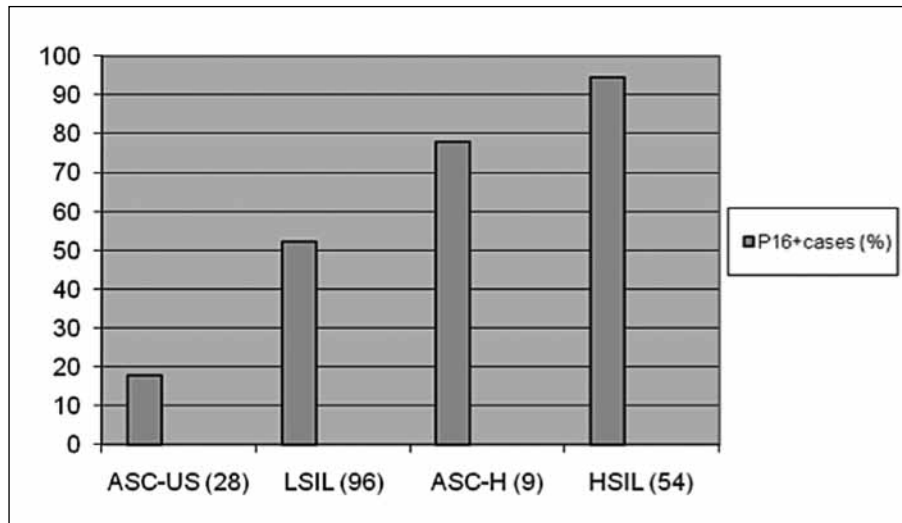


Figure 1: P16 expression in abnormal cervical cytology

Table 1: Distribution of HPV infection in cervical abnormalities

GP5+/6+ PCR+	HPV 16	HPV 18	HPV 16&18	Total†
ASC-US (25)	1	6	0	7 (28)
LSIL (87)	7	13	4	24 (27.6)
ASC-H (9)	1	0	1	2 (22.2)
HSIL (51)	12	6	3	21 (41.2)
Total†	21 (12.2)	25 (14.5)	8 (4.7)	54 (31.4)

† Totals are given as number (percentage).

Table 2: Results of P16 immunocytochemical and HPV DNA (GP5+/6+) by PCR testing on Papanicolaou smears of 182 patients with abnormal cervical cytology

Parameter	ASC-US	LSIL	ASC-H	HSIL	Total†
P16 ^{INK4A} +; PCR+	4	49	7	48	108 (59.3)
P16 ^{INK4A} +; PCR-	0	0	0	0	0 (0)
P16 ^{INK4A} -; PCR+	21	38	2	3	64 (35.2)
P16 ^{INK4A} -; PCR-	2	7	0	1	10 (5.5)
Total†	27 (14.8)	94 (51.6)	9 (4.9)	52 (28.6)	182 (100)

† Totals are given as number (percentage).

Table 3: Sensitivity, specificity, PPV, and NPV of P16 immunostaining in the Namibian cohort

Test result	Sensitivity	95% CI	Specificity	95% CI	PPV	NPV
ASC-US (n=28)	17.9	0.068-0.38	32.1	0.25-0.40	60.4	40
LSIL (n=96)	52.1	0.42-0.62	31	0.22-0.41	60	40
ASC-H (n=9)	77.8	0.40-0.96	40.4	0.33-0.48	60.4	40
HSIL (n=54)	96.3	0.86-0.99	54	0.45-0.63	60.4	40

and 0/9 ASC-H. Furthermore, the P16 protein was expressed in 7/9 HPV positive ASC-H classified cervical lesions.

To assess the diagnostic accuracy of p16^{INK4A} immunostaining for the 4 cytologic classifications, P16 immuno-expression produced 17.9% (95% CI, 0.068-0.38) sensitivity, 32.1% (95% CI, 0.25-0.40) specificity, 60.4% (95% CI, 0.53-0.67) PPV, and 40% (95% CI, 0.33-0.47) NPV in ASC-US categorized cervical lesions with 52.1% (95% CI, 0.42-0.62) sensitivity, 31% (95% CI, 0.22-0.41) specificity, 60% (95% CI, 0.53-0.67) PPV, and 40% (95% CI, 0.33-0.47) NPV for LSILs (Table 3). In addition, P16 immuno-expression produced 96.3% (95% CI, 0.86-0.99) sensitivity, 54% (95% CI, 0.45-0.63) specificity, 60.4% (95% CI, 0.53-0.67) PPV, and 40% (95% CI, 0.33-0.47) NPV in HSIL categorized cervical lesions and 77.8% (95% CI, 0.40-0.96)

sensitivity, 40.4% (95% CI, 0.33-0.48) specificity, 60.4% (95% CI, 0.53-0.67) PPV, and 40% (95% CI, 0.33-0.47) NPV in ASC-H categorized cervical lesions. Contrary to this, the specificity of HPV detection by GP5+/6+ PCR in the four cervical categories decreased to 5%, 3%, 6% and 7% for ASC-US, LSIL, ASC-H and HSIL, respectively. Similarly, the NPV for HPV detection by GP5+/6+ PCR decreased considerably in comparison to P16 immuno-expression. Statistical significances in sensitivity and PPV (p<0.001) between P16 immunostaining and HPV DNA by GP5+/6+ PCR were observed. The association between the results for the two assays was statistically significant (Spearman's rho =0.365, p<0.05). Fisher exact test for ASC-US, LSIL and HSIL categories were statistically insignificant (p>0.05).

Enhancing the diagnostic accuracy through ancillary p16 testing

Generally, the test efficiency for HPV transformation was substantially improved when positive P16 immuno-expression was integrated in the interpretation of conventional Pap-stained slides. The diagnostic sensitivity for HPV transformation in HSILs increased from 0.31 in conventional Pap staining to 0.96 in conventional Pap staining supplemented by P16 immunostaining (i.e. an increase in sensitivity of 65%). The relative increase for HPV induced cervical lesions was highest in the HSIL category (51 concordant results for conventional Pap staining plus P16 expression compared with 17 concordant results for conventional Pap staining only), followed by LSIL cases (73 for conventional Pap staining plus P16 compared to 56 for conventional Pap staining only, i.e. an increase of 30%). The diagnostic specificity increased slightly from 0.28 (conventional Pap staining) to 0.33 (conventional Pap staining plus P16) in HSILs, while the specificity in LSILs decreased from 0.82 (conventional Pap staining) to 0.5 (conventional Pap staining plus P16). The association between the results for the two assays was statistically significant ($r=0.260$, $p<0.05$). Correlating results in the respective cervical categories were as follows: ASC-US ($r=0.203$, $p=0.251$), LSIL ($r=0.277$, $p<0.05$) and HSIL ($r=0.567$, $p<0.05$). The linear by linear association in HSILs and LSILs between GP5+/6+ PCR and conventional Pap staining supplemented by P16 immunostaining ($p<0.05$) were statistically significant. Insignificant correlations were found in ASC-US ($p<0.245$) categorized lesions. There was a poor correlation between results obtained by GP5+/6+ PCR and conventional Pap staining supplemented by P16 immunostaining ($Kappa=0.079$) in ASC-US classified lesions however, slight ($Kappa=0.276$) and fair agreement ($Kappa=0.486$) in results between the two assays in LSILs and HSILs were noted, respectively. For LSILs and HSILs, there were insignificant differences in results between the two assays while in ASC-US categorized lesions, differences between two paired proportions were statistically significant (McNemar's $p<0.005$).

Association between P16 immunoexpression and HR-HPV infection stratified by cervical cytology

Expression of P16 and HR-HPV (types 16 and/or 18) infection was appraised in 108 cytologic cases incorporated in the study. As shown in table 4, positive P16 immunoexpression was detectable in 108 (62.8%) of 172 GP5+/6+ positive cervical smears examined, whereas HR-HPV (types 16 and/or 18) infection was identified in 54 (31.4%) of 172 GP5+/6+ positive samples. Among HPV-16-positive cases, two were negative, and 19 were positive for P16 expression. Among HPV-18-positive subjects, 15 were positive for P16 while 10 cases lacked P16 expression. To assess whether an association between P16 expression and HR-HPV (types 16 and/or 18) infection exist, we compared P16 immunoreactivity with HR-HPV (types 16 and/or 18) results. Forty (74.1%) of 54 HR-HPV (types 16 and/or 18) positive cases displayed P16 immunoreactivity, while 52 (44.1%) of 118 HR-HPV (types 16 and/or 18) negative cases were P16 negative. The kappa coefficient for the interassay agreement was 0.173, $p<0.05$. The McNemar test for correlated proportions suggested significant differences between the two assays for the detection of HPV ($p<0.001$). Assessing levels of P16 expression in different cervical lesion grades, we observed that five (17.9%) of 28 ASC-US cases demonstrated P16 expression, of which two were

HR-HPV infected: HPV type 16 (3.6%) and HPV type 18 (3.6%). Notably, five ASC-US cases (17.9%) were HR-HPV+ but P16-. In the HPV types 16 & 18-negative ASC-US category, 16 of 28 cases (57.1%) were negative and two (7.1%) were positive for P16 immunoreactivity. The association between HR-HPV (types 16 and/or 18) positivity and P16 expression in ASC-US classified lesions were statistically insignificant (chi-square, Pearson, 0.209, $p=0.235$). Of 87 LSIL cases, 16 (18.4%) showed both P16 immunoreactivity and the presence of HPV types 16 and/or 18. Nonetheless, 32 (49.2%) of 65 LSIL cases that were HR-HPV (types 16 and/or 18) negative, showed P16 expression. The association between HR-HPV (types 16 and/or 18) positivity and P16 expression in LSILs were statistically insignificant at the 0.05 level (chi-square, Pearson, $p=0.254$). Of 21 HR-HPV (types 16 and/or 18) positive HSILs, two (9.5%) lacked the P16 protein while three ASC-H samples were both HR-HPV+ and P16+. The association between HR-HPV types 16 and/or 18 positivity and P16 expression in HSILs were not statistically significant (chi-square, Pearson 0.174, $p=0.203$).

DISCUSSION

In our study, a link between modified P16 expression as a diagnostic adjunct for the triage of patients with abnormal cervical cytology, and the presence of HPV in cervical abnormalities has been demonstrated. Both P16 expression and HR-HPV (types 16 and 18) positivity correlate significantly. Positive p16^{INK4A} immuno-reactivity for HR-HPV type 16 was significantly lower than those for HPV-type 18; the latter believed to be the most aggressive HPV type with a high rate of disease recurrence^[23]. Positive immunoreactivity potentially identifies those cases where viral DNA has disrupted the function and expression of host genes and development to cervical carcinoma has commenced.

Similar to our findings in which HPV DNA by PCR was detected in all P16 immunoreactive cases, Yildiz *et al.*, 2007^[24] also found that all P16+ cases demonstrated the presence of HPV; although not all HPV+ cases expressed the P16 protein. These findings were corroborated by Lin *et al.*, 2005^[25] who concluded that P16 expression is independent of an individual's HPV status and may serve as an indicator for carcinogenesis in squamous and glandular epithelium of the cervix. In fact, they reported the presence of HPV DNA by PCR in 40% of CIN I, 75% of CIN II and in 50% of CIN III lesions while P16 expression were observed in 96.7% histologically diagnosed lesions. Similarly, Kalof *et al.*, 2005^[26] reported P16-positive CIN1 cases, which were HPV-negative by *in situ* hybridization PCR. In view of this data, HPV-unrelated P16 expression is areas of further research.

P16 expression was considerably higher in HSILs compared to all other cytological categories, noticeably discriminating HSIL from classifications such as ASC-US or LSIL. In fact, this low-risk group (ASC-US and LSIL) are frequently related to transient HPV infections that resolve spontaneously and do not require intervention^[27]. Nonetheless, Kinney *et al.*, 1998^[28] in his report found that 68.6% of HSILs in biopsies were preceded by ASC-US and LSIL classified cytological lesions, demonstrating that these categories may constitute a specific entity in the cervical disease progression. Of importance, we demonstrated the presence of HPV DNA by GP5+/6+ PCR in 98%, 52% and 20 % of P16+ HSILs, LSILs and ASC-US classified lesions, respectively.

Table 4: Type specific PCR and P16 immunocytochemical results for HPV detection among patients with abnormal cervical cytology

Parameter	ASC-US	LSIL	ASC-H	HSIL	Total†
HPV16+; P16 ^{INK4A} +	1	6	2	10	19 (11)
HPV16-; P16 ^{INK4A} -	13	17	0	0	30 (17.4)
HPV16+; P16 ^{INK4A} -	1	1	0	0	2 (1.2)
HPV16-; P16 ^{INK4A} +	1	17	3	22	43 (25)
HPV18+; P16 ^{INK4A} +	1	7	1	6	15 (8.7)
HPV18-; P16 ^{INK4A} -	3	16	1	0	20 (11.6)
HPV18+; P16 ^{INK4A} -	4	3	1	2	10 (5.8)
HPV18-; P16 ^{INK4A} +	1	15	1	8	25 (14.5)
HPV16&18+; P16 ^{INK4A} +	0	3	0	3	6 (3.5)
HPV16&18+; P16 ^{INK4A} -	0	2	0	0	2 (1.2)
Total†	25 (14.5)	87 (50.6)	9 (5.2)	51 (29.7)	172 (100)

† Totals are given as number (percentage)

Our results were found to be consistent with the results of Pientong *et al.*, 2004^[29] in which HPV by MY09 plus MY11 PCR was detected in 70%, 57% and 45% of HSIL, LSIL and ASC-US classified lesions. Though their results are proportionally related to our results with respect to the severity of the cervical lesion, discordances in ASC-US and HSILs may be attributed to incorrect morphological interpretation of the conventional smear having had a high false positive rate^[2-3].

We found a high sensitivity for p16^{INK4A} staining in HSIL (96.3%) with a low sensitivity of 17.9% demonstrated in ASC-US. Equally, a specificity of 54% and 31% was detected in HSIL and LSIL, respectively. Unequivocally, P16 expression correlated significantly to the grade of cervical lesion, being more common in HSIL categorized cervical lesions. Moreover, HR-HPV (types 16 and/or 18) infection was virtually related to p16^{INK4A} reactivity with 40 out of 54 (74.1%) HR-HPV (types 16 and/or 18) positive cases expressing p16^{INK4A} immunoreactivity. These results are in agreement with the findings from another researcher^[30]. Interestingly, Sahebali *et al.*, 2004^[31] demonstrated a strong relationship between the quantity of P16-positive cells and the HPV type, being more frequently in HPV type 16. They concluded that this association expresses a clinical significant sign, with greater numbers of P16-positive cells identified in HSILs than other diagnostic classifications. Coincident with other studies^[32], we used a threshold of 5 or more P16-positive cells as a cut-off point in differentiating abnormal lesions from lesions represented as "NILM". Though this is a limitation in this study, we did not employ staining intensity and a nuclear scoring system as used by Tsoumpou *et al.*, 2009^[33]. Moreover, Hu *et al.*, 2004^[34] reported that diffuse staining is related to the presence of HPV types 16/18.

By examining the respective cytologic categories in aggregate, p16^{INK4A} immunostaining and conjunctive conventional cytology reflected dissimilar sensitivities (61.1% vs 45.6%) whereas adjunctive p16^{INK4A} in ASC-US classified cervical lesions was more specific than HR-HPV types 16 and 18 combined (85.7% vs 76.2%). Moreover, the PPV of p16^{INK4A} was greater than that for HR-HPV (types 16 and/or 18) in LSIL categorized cervical lesions (60.5% vs 25.3%). Similarly, the sensitivity and specificity of P16 expression in HSILs were better than HR-HPV types 16 and 18 being 96.3% and 54.1%, respectively. The dependability of HPV types 16 and 18 on the tests' diagnostic accuracy was inferior to that of the P16 protein. Potential reasons for this

discrepancy include the presence of other HR-HPV types that are not accounted for, due to the design of our study as we mainly focused on the identification of HR-HPV types 16 and 18. Another possible explanation is that not all HPV infections may develop into clinically significant cervical abnormalities. These results were consistent with the results from other studies^[35] in which a sensitivity, specificity, PPV, and NPV for p16^{INK4A} immunostaining of 68.8%, 26.3%, 28.2%, and 66.7% were demonstrated, respectively.

The combination of cytologically diagnosed condylomata acuminata as depicted by koilocytotic changes and P16 expression provided a greater diagnostic specificity (56.3% vs 5.2% vs 39%) than HPV DNA by PCR or p16^{INK4A} alone. These data clearly demonstrated the superiority of conjunctive P16 testing to conventional cytologic screening, suggesting that the combination of conventional cytology and p16^{INK4A} assay has a better diagnostic accuracy than HPV DNA by PCR. Thus, the combination test has a superior diagnostic performance. The sensitivity for detecting HPV transformation (P16 expression and cellular koilocytosis) in HSILs improved considerably: the number of missed HPV-induced lesions decreased by 65%, and the number of overlooked HPV cell-transformation in LSIL classified lesions were reduced by 30%. This gain in sensitivity was accompanied by a relative loss in specificity, which could be attributed to the lack of a well-defined nuclear scoring system. These observations further support the utility of P16 immunocytochemical testing as a reflex test in conjunction with cervical cytology, following a Pap cytologic result of ASC-US or HSIL. On the other hand, no meaningful association between P16 protein detection and HR-HPV (types 16 and/or 18) infection in LSILs was established in our study. Similarly, no direct correlation between P16 expression and the presence of HPV 16/18 in histologically diagnosed LSILs was found^[36].

Our findings clearly demonstrated that the p16^{INK4A} immunoassay in conjunction with conventional cytology show potential to identify modifications of the HPV expression profile to the transforming stage. Not compromising the diagnostic sensitivity, this could be a useful test in a setting with higher specificity for the detection of HPV transformation, particularly in LSILs. As an added advantage, the p16^{INK4A} immunocytochemical stain may also be used on decolorized conventional Pap smears, permitting "reflexing" ASC-US or LSIL Pap cytologic results directly to P16 cytologic testing, even when conventional Pap smears are

used. This may further escalate cost reduction and an increase in the test diagnostic accuracy, especially in triaging ASC-US and LSIL Pap cytologic results. Mindful that a cost-effectiveness analysis has not yet been conducted, it might be sensible to predict that expensive treatment regimes such as colposcopy referrals for ASC-US Pap cytologic results can be reduced by using the p16^{INK4A} test for the detection of potentially progressive cervical lesions.

CONCLUSION

We conclude that, not only is P16 expression a marker for pathogenic activity of HR-HPV, but through correlative assessments,

direct visualization of P16 immuno-expression in cytological smears seems to be a more effective method than HR-HPV by PCR.

ACKNOWLEDGEMENT

This research was made possible by a grant from the Cancer Association of Namibia, the National Research Foundation (NRF) and the Cape Peninsula University of Technology (CPUT).

REFERENCES

- Niemenen P, Kallio M, Anttila A, Hakama M. Organised vs. spontaneous Pap-smear screening for cervical cancer: a case-control study. *Int J Cancer* 1999; 83:55-8.
- Fahey MT, Irwig L, Macaskill P. Meta-analysis of Pap test accuracy. *Am J Epidemiol* 1995; 141:680-9.
- Sherman ME, Schiffman MH, Lorinez AT, et al. Toward objective quality assurance in cervical cytopathology: correlation of cytopathologic diagnoses with detection of high-risk human papillomavirus types. *Am J Clin Pathol* 1994; 102:182-7.
- Munoz N, Bosch FX, de Sanjose S, et al.; International Agency for Research on Cancer Multicenter Cervical Cancer Study Group. Epidemiologic classification of human papillomavirus types associated with cervical cancer. *N Engl J Med* 2003; 348:518-27.
- Cogliano V, Baan R, Straif K, Grosse Y, Secretan B, El Ghissassi F; WHO International Agency for Research on Cancer. Carcinogenicity of human papillomaviruses. *Lancet Oncol* 2005; 6:204.
- Kjaer S, Hogdall E, Frederiksen K, et al. The absolute risk of cervical abnormalities in high-risk human papillomavirus-positive, cytologically normal women over a 10-year period. *Cancer Res* 2006; 66: 10630-6.
- Khan MJ, Castle PE, Lorincz AT, et al. The elevated 10-year risk of cervical precancer and cancer in women with human papillomavirus (HPV) type 16 or 18 and the possible utility of type-specific HPV testing in clinical practice. *J Natl Cancer Inst* 2005; 97:1072-9.
- Castle PE, Solomon D, Schiffman M, Wheeler, CM. Human papillomavirus type 16 infections and 2-year absolute risk of cervical precancer in women with equivocal or mild cytologic abnormalities. *J Natl Cancer Inst* 2005; 97:1066-71.
- Smith JS, Lindsay L, Hoots B, et al. Human papillomavirus type distribution in invasive cervical cancer and high-grade cervical lesions: a meta-analysis update. *Int J Cancer* 2007; 121:621-32.
- Clifford G, Franceschi S, Diaz M, Munoz N, Villa LL. Chapter 3: HPV type distribution in women with and without cervical neoplastic diseases. *Vaccine* 2006; 24 Suppl 3:S26-34.
- Lorincz AT, Richart RM. Human papillomavirus DNA testing as an adjunct to cytology in cervical screening programs. *Arch Pathol Lab Med.* 2003; 127:959-968.
- Walboomers JM, Jacobs MV, Manos MM, et al. Human papillomavirus is a necessary cause of invasive cervical cancer worldwide. *J Pathol* 1999; 338:12-9.
- Ho GY, Bierman R, Beardsley L, Chang CJ, Burk RD. Natural history of cervicovaginal papillomavirus infection in young women. *N Eng J Med* 1998; 338:423-8.
- Klaes R, Benner A, Friedrich T, et al. p16^{INK4a} immunohistochemistry improves interobserver agreement in the diagnosis of cervical intraepithelial lesions. *Am J Surg Pathol* 2002; 26:1389-1399.
- Jalil H and Oster A. The negative predictive value of p16^{INK4a} to assess the outcome of cervical intraepithelial neoplasia 1 in the uterine cervix. *Int J Gyn Pathol* 2007; 26:223-228.
- Nieh S, Chen SF, Chu TY, Lai HC, Fu E. Expression of p16^{INK4a} in Papanicolaou smears containing atypical squamous cells of undetermined significance from the uterine cervix. *Gynecol Oncol* 2003; 91:201-208.
- Nieh S, Chen SF, Chu TY, Lai HC, Fu E. Expression of p16^{INK4a} in Papanicolaou smears containing atypical glandular cells from the uterine cervix. *Acta Cytol* 2004; 48:173-180.
- Pientong C, Ekalaksananan T, Swadpanich U, et al. Immunocytochemical detection of p16^{INK4a} protein in scraped cervical cells. *Acta Cytol* 2003; 47:616-623.
- Sahebali S, Depuydt CE, Segers K, et al. p16^{INK4a} as an adjunct marker in liquid-based cervical cytology. *Int J Cancer* 2004; 108:871-876.
- Solomon D, Davey D, Kurman R, et al. The 2001 Bethesda System: terminology for reporting results of cervical cytology. *JAMA* 2002; 287:2114-2119.
- Rughooputh S, Eddoo R, Manraj S, Jeebun N, Greenwell P. Detection of human papillomavirus from archival tissues in cervical cancer patients in Mauritius. *J Clin Virol* 2006; 35: 173-178.
- Grainge MJ, Seth R, Guo L, Neal KR, Coupland C, Vryenhoef P, Johnson J, Jenkins D. Cervical human papillomavirus screening among older women. *J Infect Dis* 2005; 11 (11): 1680-1685.
- DeVita VT, Hellman S, Rosenberg SA. eds. Cancer: Principles and Practice of Oncology, 6th edition. Philadelphia, PA: Lippincott Williams & Wilkins, 2001:1526-1553.
- Yildiz IZ, Usulutun A, Firat P, Ayhan A, Kucukali T. Efficiency of immunohisto-chemical p16 expression and HPV typing in cervical squamous intraepithelial lesion grading and review of the p16 literature. *Pathology – Research and Practice* 203; 2007; 445-449
- Lin ZH, Jin SZ, Lee KY, Kim E, Kim HI. Human papillomavirus genotyping by oligonucleotide microarray and p16^{INK4A} expression in uterine cervical intraepithelial neoplasm and invasive carcinoma in Korean women. *Pathol. Int.* 55; 2005; 491-496.
- Kalof AN, Evans MF, Simmons-Arnold L, Beatty BG, Cooper K. p16^{INK4a} immunorexpression and HPV in situ hybridization signal patterns: potential markers of high-grade cervical intraepithelial neoplasia. *Am. J. Surg. Pathol* 2005; 5: 674-679.
- Plummer M, Schiffman M, Castle PE, Maucourt-Boulch D, Wheeler CM; ALTS Group. A 2-year prospective study of human papillomavirus persistence among women with a cytological diagnosis of atypical squamous cells of undetermined significance or low-grade squamous intraepithelial lesion. *J Infect Dis* 2007; 195:1582-1589.
- Kinney WK, Manos M, Hurley LB, Ransley JE. Where's the high-grade cervical neoplasia? The importance of minimally abnormal Papanicolaou diagnoses. *Obstet Gynecol* 1998; 91:973-976.
- Pientong C, Ekalaksananan T, Kongyingyoes B, et al. Immunocytochemical staining of p16^{INK4a} protein from conventional Pap test and its association with human papillomavirus infection. *Diagn Cytopath* 2004; 31:4.
- Bolanca IK and Ciglar S. Evaluation of p16^{INK4a} in cervical lesion of premenopausal and postmenopausal women. *Coll Antropol* 2007; 2:107-11.
- Sahebali S, Depuydt CE, Segers K, et al. p16^{INK4a} as an adjunct marker in liquid-based cervical cytology. *Int J Cancer* 2004; 108: 871-6.

32. Guo M, Hu L, Baliga M, He Z, Hughson MD. The predictive value of p16^{INK4a} and Hybrid Capture 2 human papillomavirus testing for high-grade cervical intraepithelial neoplasia. *Am J Clin Pathol* 2004; 122:894-901.
33. Tsoumpou I, Arbyn M, Kyrgiou M, et al. p16^{INK4a} immunostaining in cytological and histological specimens from the uterine cervix: a systematic review and meta analysis. *Cancer Treatment Rev* 2009; 35:210-220.
34. Hu LL, Guo M, Liu S, et al. p16^{INK4a} expression and human papillomavirus types 16/18 infection in cervical intraepithelial neoplasm of adolescents [abstract]. *Mod Pathol* 2004; 17(suppl 1):831.
35. Shin EK, Lee SR, Kim MK, et al. Immunocytochemical staining of p16^{INK4a} protein as an adjunct test in equivocal liquid-based cytology. *Diagn Cytopath* 2007; 36:5.
36. Guimaraes MC, Goncalves MA, Soares CP, Bettini JS, Duarte RA, Soares EG. Immunohistochemical expression of p16^{INK4a} and bcl-2 according to HPV type and to the progression of cervical squamous intraepithelial lesions. *J Histochem Cytochem* 2005; 53:509-16.