Toxicology and Environmental Health Sciences (2025) 17:565–577
https://doi.org/10.1007/s13530-025-00280-w

ORIGINAL ARTICLE

Rutin and vitamin E restore cobalt chloride-induced cardiorenal toxicity

Ebunoluwa Racheal Asenuga[1] · Omolola Victoria Awoyomi[2] · Temitayo Olabisi Ajibade[3] · Oluwaseun Olanrewaju Esan[4] · Moses Olusola Adetona[6] · Taiwo Olaide Oyagbemi[2] · Adewumi Victoria Adeogun[3] · Olumayowa Olawumi Igado[5] · Ebenezer Oyedele Ajiboye[7] · Ademola Adetokunbo Oyagbemi[3] · Temidayo Olutayo Omobowale[4] · Olufunke Eunice Ola-Davies[3] · Adebowale Benard Saba[8] · Adeolu Alex Adedapo[8] · Sanah Malomile Nkadimeng[9] · Evaristus Nwulia[10] · Oluwafemi Omoniyi Oguntibeju[11] · Momoh Audu Yakubu[12]

Received: 17 June 2025 / Accepted: 16 September 2025 / Published online: 23 October 2025
© The Author(s), under exclusive licence to Korean Society of Environmental Risk Assessment and Health Science 2025

Abstract

Objective Cobalt is an essential nutrient for humans and animals due to its presence and involvement in the synthesis of vitamin B_{12} (cobalamin). However, toxicity could arise from chronic exposure or high dosages, thereby impacting negatively on organ functions such as heart and kidney. This study aimed to ascertain if rutin and vitamin E could reverse cobalt chloride-induced cardiorenal toxicity.

Methods Thirty-five (35) male Wistar rats were divided randomly into five groups of seven rats each as follows: Group A-Control (clean water only), Group B-Cobalt chloride (300 ppm) ($CoCl_2$) only in drinking water, Group C-Rutin (100 mg/kg) and cobalt chloride (300 ppm) ($R_1 + CoCl_2$), Group D-Rutin (200 mg/kg) and cobalt chloride (300 ppm) ($R_2 + CoCl_2$), and Group E-Vitamin E (50 mg/kg) and cobalt chloride (300 ppm) (Vit. $E + CoCl_2$); all for 7 days. At the end of the experiment, blood pressure parameters were taken, cardiac and renal biomarkers of oxidative stress and antioxidant, histology, and immunohistochemistry were determined.

Results Elevated blood pressure in Cobalt Chloride ($CoCl_2$) group reduced significantly in dose dependency in treated $CoCl_2$ groups with vitamin E and Rutin. At the end of the experiment, administration of $CoCl_2$ to rats showed a significant increase in the blood pressure parameters when compared to the control, respectively. Also, $CoCl_2$ administration altered the activity and concentration of cardiac, and renal antioxidant markers, and serum levels of nitric oxide, hydrogen peroxide and malondialdehyde while rutin and vitamin E ameliorated this effect in a dose-dependent manner. Little or no visible lesion was observed in groups treated with rutin and vitamin E following histopathological assessment of the heart and kidney tissue. The immunopositivity of cardiac troponin, renal mineralocorticoid receptor and nuclear factor kappa beta was low in groups exposed to rutin and Vitamin E.

Conclusion Cobalt chloride has been shown to induce cardio and renal toxicity and this study was able to show the ameliorative effect of rutin and vitamin E in a dose-dependent manner.

Keywords Reactive oxygen species · Rutin · Vitamin E · Cobalt chloride · Antioxidant

Introduction

Cobalt, a trace element found in the diet as a component of Vitamin B_{12}, functions biologically as a co-factor in several enzyme-catalyzed reactions [1]. It is toxic to biological tissues when exposed to it in large quantities [2]. The metal has broad applications in domestic, agricultural, industrial, and medical settings, leading to emerging alarms about the likelihood of extensive exposure to toxic levels of the metal [1]. Cobalt mechanisms of toxicity involve reactive oxygen species (ROS) production, apoptosis induction and hypoxia-inducible factor (HIF) activation [3]. Cardiomyopathies in heavy drinkers of beer containing cobalt as a foam-stabilizing agent and also in industrial metal workers have been identified [4]. More recent reports also validate the incidence of cardiotoxicity and cardiorenal dysfunctions after extreme exposure to cobalt [5–9].

Extended author information available on the last page of the article

The kidney is a critical target for xenobiotics and is also very prone to adverse effects of metals exposure including cobalt [10]. Several pieces of evidence have linked cellular and organ dysfunctions between the heart and kidneys, in a group of conditions collectively known as cardio-renal syndromes (CRS) [1]. Though different pathways have been identified to provide a mechanistic relationship between the two organs, oxidative stress is believed to be central as a primary mechanism enhancing tissue injury and cellular dysfunction in different cases of CRS. The human body has developed several mechanisms to counter oxidative stress by producing antioxidants, either naturally or supplied externally through foods and/or supplements to scavenge free radicals, thus inhibiting and repairing ROS-caused damages [11, 12]. Hence, naturally or externally supplied antioxidants can enhance the immune defence and lower the risk of degenerative diseases [12].

Rutin, a citrus flavonoid glycoside comprises of the disaccharide rutinose and the flavonol quercetin [13]. This polyphenolic bioflavonoid has extensive pharmacological activities and also considerable antioxidant properties. It mostly serves as an antioxidant along with anti-inflammatory, anticancer, and anti-diabetic agents [14], in comparison with other bioflavonoids, rutin has significantly lower toxicity, in an experimental animal model. These qualities propose that rutin may well be a highly effective and relatively safe antioxidant. Vitamin E has been known to have antioxidative properties and, therefore can help avert diseases associated with oxidative stress, such as cardiovascular disease, chronic inflammation, cancer, and neurological disorders [15]. By direct scavenging, vitamin E may inhibit free radical production and subsequent changes of the antioxidant species into a less toxic product [1]. This study, therefore, aims at investigating the ameliorative effect of rutin and vitamin E in cobalt chloride-induced toxicity-treated rats.

Materials and methods

Chemicals and reagents

All chemicals and reagents used in this study were of analytical grade.

Experimental design

Thirty-five (35) male Wistar rats were obtained from the animal house of the Faculty of Veterinary Medicine of the University of Ibadan. The selected animals were kept in plastic cages and allowed to adapt for 2 weeks after which their weights were > 170–250 g before the experiment. The selected animals had free access to tap water and a standard daily diet of rodents. The animals were exposed to a natural photoperiod of about 12 h of light and 12 h of darkness daily.

Experimental groups and protocols

The rats were divided randomly into five groups of seven rats each as follows: Group A-Control (clean water only), Group B-Cobalt chloride (300 ppm) ($CoCl_2$) only in drinking water, Group C-Rutin (100 mg/kg) and cobalt chloride (300 ppm) ($R_1 + CoCl_2$), Group D-Rutin (200 mg/kg) and cobalt chloride (300 ppm) ($R_2 + CoCl_2$), and Group E – Vitamin E (50 mg/kg) and cobalt chloride (300 ppm) (Vit. $E + CoCl_2$); all for 7 days. Cobalt chloride was administered through drinking water while rutin and vitamin E were administered by oral gavage. The dosage and the duration of $CoCl_2$ administration was based on our previous research report [16]**.** A blood pressure measurement was done on day 8. Blood samples were collected, and animals were sacrificed on day 9 by cervical dislocation and, hearts and kidneys were collected. Proper animal handling protocols were followed [17].

Blood pressure measurement protocol

An automated blood pressure monitor (CODA S1, Kent Scientific Corporation, Connecticut, USA) was used in taking the blood pressure parameters of the rats. The systolic (SBP), diastolic (DBP), and mean arterial (MAP) blood pressures were determined non-invasively in conscious animals by tail plethysmography as reported from our laboratory [18]. The rats body temperature was maintained by setting the blood pressure warming platform to 37 °C.

Tissue preparation for biochemical assays

Using the orbital venous plexus bleeding route; under xylazine/ketamine anesthesia (o.1 mL/100 g body weight), blood was collected during sacrifice with the aid of clean capillary tubes into plain sterilized tubes and allowed to clot. The clotted blood samples were centrifuged at 4,000 g for 10 min and the serum was harvested for analysis. Excised hearts and kidneys were rinsed quickly in cold normal saline after which they were blotted with filter paper and weighed. The heart and kidneys were then minced with scissors in 4 volumes of homogenizing phosphate buffer, pH 7.4, and homogenized using a Teflon homogenizer. The homogenates were then centrifuged at 10,000 rpm, at −4 °C for 10 min to obtain the post mitochondria fraction. The supernatants were collected and stored for biochemical evaluations in −40 °C freezer.

Biochemical assay

Quantification of protein concentration

This was done according to the Biuret method as described by Gornal et al. [19]. using bovine serum albumin (BSA) as standard.

Assessment of antioxidant defence system markers

By measuring the inhibition of auto-oxidation of epinephrine at pH 10.2 at 30 °C as described by Misra and Fridovich [20]. The superoxide dismutase (SOD) activity was determined with slight modification from Oyagbemi et al. [21] [15]. Briefly, 800 µL of Tris-KCl buffer was added into a test tube, then 250 µL of trichloroacetic acid was added followed by an addition of 250 µL of thiobarbituric acid, then 20 µL of sample was added. The mixture formed was incubated in a water bath at 80 °C for 45 min, cooled on ice and centrifuged at 4000 rpm for 5 min. Subsequently, the supernatant was decanted and placed in micropipette plate reader and the absorbance was measured against a reference blank of distilled water at 490 nm wavelength.

Jollow et al. [22] procedure was used in estimating the level of reduced glutathione (GSH). The reduced glutathione in the cardiac and renal tissues was assayed based on the principle that the thiol moiety in glutathione exhibits a reduction reaction with 5,5′-dithiobis-2-nitrobenzoic acid (DTNB) to form 5-thio-2-nitrobenzoic acid which is yellow in colour and can be detected spectrophotometrically at 412 nm wavelength. The absorbance was read at 412 nm wavelength.

According to Habig et al. [23], the activity of glutathione S-transferase was quantified as described by the ability of the enzyme to catalyze the conjugation of GSH with 1-chloro-2, 4-dinitrobenzene (CDNB) over a time period of about 3 min with absorbance read at 340 nm in 30 s intervals.

Glutathione peroxidase (GPx) activity was also assessed according to Beutler et al. [24]. The reaction mixture containing 0.5 mL of phosphate buffer, 0.1 mL sodium nitrate ($NaNO_3$), 0.2 mL glutathione (GSH), 0.1 mL hydrogen peroxide (H_2O_2), 0.5 mL sample and 0.6 mL of distilled water. This mixture was incubated at 37 °C for 5 min. Thereafter, 0.5 mL of trichloroacetic acid (TCA) was added and centrifugation was done at 3000 rpm for 5 min. The absorbance was read at 412 nm wavelength against blank.

Estimation of oxidative stress markers

The malondialdehyde (MDA) level was calculated according to the procedure of Vashney and Kale [25]. Briefly, 0.2 mL of sample was added to a solution containing 0.8 mL Tris-potassium chloride and 0.25 mL trichloroacetic acid, before the addition of 0.25 mL of thiobarbituric acid. Then, the reaction mixture was placed in a boiling water bath for 30 min. Thereafter, the preparation was allowed to cool on ice, centrifuged for 15 min at 4000 r/min, and read spectrophotometrically at 532 nm wavelength.

Following the procedure, Wolff´s [26] hydrogen peroxide (H_2O_2) level was assessed. The assay for hydrogen peroxide (H_2O_2) was carried out by adding 50 µL of cardiac and renal sample to a solution prepared from potassium phosphate buffer, ammonium ferrous sulfate, sorbitol, xanthine oxidase and sulfuric acid, and subsequently vortexed.

Production of NO was estimated by evaluating the concentration of nitrite using Griess reagent as described by Olaleye et al. [27]. Griess Reagent (0.1 mL), sample (0.1 mL) in a cuvette and allowing the reaction to proceed for 30 min at room temperature. Then the absorbance was read at 540 nm wavelength.

Immunohistochemistry and histopathology

For immunohistochemistry, paraffin-embedded tissue samples from the kidney and heart were prepared as described by Oyagbemi et al. [18]. Slides were charged at 37 °C for four days, then deparaffinized in xylene and rehydrated in ethanol. Antigen retrieval was performed using citrate buffer, followed by cooling and rinsing in PBS. Endogenous enzyme activity was blocked with HRP-conjugated antibodies, and nonspecific binding was prevented using normal goat serum. Primary antibodies (cardiac troponin, renal mineralocorticoid receptor, and nuclear factor kappa beta (NF-κB) were incubated for 2 h. Thereafter, secondary HRP-conjugated antibodies were applied, and chromogenic signals were developed with DAB. The counterstaining of the slides was done with haematoxylin, dehydrated, cleared in xylene, and mounted with coverslips. Finally, slides were examined under a light microscope for chromogenic staining and tissue analysis.

The histopathological procedure was previously described by Drury et al. [28]. The portion of the tissue preserved in formalin was fixed in 10% formol saline for 48 h and dehydrated sequentially in ascending grades of alcohol for 2 h. The tissues were then cleared in chloroform overnight and embedded in molten paraffin wax for an hour. The embedded tissues were sectioned, floated on water bath at 5–10 °C and later dried on the hot plate for 30 min at 60 °C. The tissues were dewaxed in xylene for 30 min and rehydrated in descending grades of alcohols (100, 95, 80, 70%). These was finally rinsed in water and stained with Haematoxylin and Eosin (H&E) before examining under the light microscope for pathological changes.

Statistical analysis

All values were expressed as mean ± S.D. One-way ANOVA with Tukey's post-test was also performed using Graph Pad Prism version 8.00.

Results

In (Table 1), there was an increase in the systolic, diastolic blood pressure and mean arterial pressure by 39%, 63% and 28% in cobalt chloride-treated rats when compared to control. Also, a significant ($p < 0.05$) increase in the systolic (8%), diastolic (35%), and arterial mean pressure (12%) was observed in $R_1 + CoCl_2$ relative to the control (Table 1). However, a significant ($p < 0.05$) decrease in the systolic (22%), diastolic (17%), and arterial mean pressure (19%) was observed in $R_1 + CoCl_2$ relative to $CoCl_2$ only (Table 1). Also, a significant ($p < 0.05$) decrease in systolic pressure (25% and 28%), diastolic pressure (37% and 38%) and arterial mean pressure (30% and 21%) in $R_2 + CoCl_2$ and Vit. $E + CoCl_2$, respectively, relative to $CoCl_2$ only (Table 1). Results in (Table 2) showed a significant ($p < 0.05$) increase in the cardiac (37%) and renal (61%) levels of hydrogen peroxide in rats treated with $CoCl_2$ only when compared to the control. However, there was a significant ($p < 0.05$) decrease in the cardiac and renal level of hydrogen peroxide in $R_1 + CoCl_2$ (29%, 30%), $R_2 + CoCl_2$ (29%, 31%) and Vit. $E + CoCl_2$ (31%, 21%) treated rats relative to $CoCl_2$ only (Table 2). Meanwhile, a significant ($p < 0.05$) increase was observed in the renal level of hydrogen peroxide in $R_1 + CoCl_2$ (12%), $R_2 + CoCl_2$ (11%) and Vit. $E + CoCl_2$ (27%) treated rats relative to control (Table 2).

Also, there was a significant ($p < 0.05$) increase in the MDA level by 348% and 74% in both cardiac and renal tissues respectively in $CoCl_2$-only treated rats when compared to the control (Table 2). In addition, a significant ($p < 0.05$) increase in the cardiac MDA level was seen in $R_1 + CoCl_2$ (157%), $R_2 + CoCl_2$ (78%) and Vit. $E + CoCl_2$ (66%) treated rats relative to the control (Table 2). Meanwhile, a significant ($p < 0.05$) decrease in the cardiac and renal MDA level was seen in $R_1 + CoCl_2$ (43%, 39%), $R_2 + CoCl_2$ (60%, 54%) and Vit. $E + CoCl_2$ (63%, 59%) treated rats when compared to $CoCl_2$ only. Also, a significant ($p < 0.05$) decrease was observed in renal MDA level in $R_2 + CoCl_2$ (20%) and Vit. $E + CoCl_2$ (28%) treated rats when compared to control (Table 2).

Table 1 Effect of Rutin and Vitamin E on the blood pressure in cobalt chloride treated rats

Groups	Systolic (mmHg)	Diastolic (mmHg)	Mean arterial pressure (mmHg)
Control	114.33 ± 2.522	78.00 ± 2.94	97.20 ± 8.11
$CoCl_2$ Only	158.70 ± 4.42[a]	126.83 ± 3.25[a]	134.10 ± 6.97[a]
$R_1 + CoCl_2$	123.80 ± 5.45[a,b]	105.25 ± 7.68[a,b]	108.71 ± 9.89[a,b]
$R_2 + CoCl_2$	118.67 ± 8.02[b]	80.20 ± 5.91[b]	94.00 ± 10.27[b]
Vit. $E + CoCl_2$	114.67 ± 5.65[b]	79.20 ± 7.50[b]	106.20 ± 7.85[a,b]

Values are expressed in mean ± SD

a-Significantly different from the control ($p < 0.05$)

b-Significantly different from the $CoCl_2$ only ($p < 0.05$)

$CoCl_2$- Cobalt chloride (300 ppm)

R_1- Rutin (100 mg/kg)

R_2- Rutin (200 mg/kg)

Vit. E- Vitamin E (50 mg/kg)

Table 2 Effect of Rutin and Vitamin E on the levels of malondialdehyde and hydrogen peroxide in Cobalt chloride treated rats

Groups	Hydrogen Peroxide (H_2O_2) (μmol/mg protein)		Malondialdehyde (MDA) (U/mg protein)	
	Heart	Kidney	Heart	Kidney
Control	34.90 ± 1.64	40.50 ± 1.39	8.81 ± 0.64	20.40 ± 0.49
$CoCl_2$ only	47.70 ± 2.16[a]	65.00 ± 2.89[a]	39.50 ± 2.56[a]	35.40 ± 2.84[a]
$R_1 + CoCl_2$	34.30 ± 1.88[b]	45.40 ± 1.73[a, b]	22.60 ± 3.19[a, b]	21.60 ± 2.15[b]
$R_2 + CoCl_2$	33.80 ± 2.21[b]	44.90 ± 2.10[a, b]	15.70 ± 2.16[a, b]	16.40 ± 1.9[a, b]
Vit. $E + CoCl_2$	32.80 ± 1.99[b]	51.60 ± 1.36[a, b]	14.60 ± 1.90[a, b]	14.70 ± 1.54 [a, b]

Values are expressed in mean ± SD

a-Significantly different from the control ($p < 0.05$)

b-Significantly different from the $CoCl_2$ only ($p < 0.05$)

$CoCl_2$- Cobalt chloride (300 ppm)

R_1-Rutin (100 mg/kg)

R_2-Rutin (200 mg/kg)

Vit. E-Vitamin E (50 mg/kg)

Results from (Fig. 1a) showed a significant ($p < 0.05$) increase in the cardiac activity of superoxide dismutase (SOD) in $CoCl_2$ (9%), $R_1 + CoCl_2$ (8%), $R_2 + CoCl_2$ (6%) and Vit. $E + CoCl_2$ (8%) treated rats when compared to control. However, a significant ($p < 0.05$) reduction in the cardiac activity of SOD in $R_1 + CoCl_2$ (1.1%), $R_2 + CoCl_2$ (1.59%) and Vit. $E + CoCl_2$ (1.1%) treated rats when compared to $CoCl_2$ only. Also, a significant ($p < 0.05$) increase in the renal activity of SOD (4%) in $CoCl_2$ only was observed when compared to the control. While, a significant ($p < 0.05$) decrease was observed in $R_1 + CoCl_2$ (3%), $R_2 + CoCl_2$ (3%) and Vit. $E + CoCl_2$ (4%) treated rats when compared to $CoCl_2$ only (Fig. 1a).

Figure 1b showed a significant ($p < 0.05$) increase in the cardiac activity of glutathione peroxidase (GPx) in $CoCl_2$ only (45%) and $R_1 + CoCl_2$ (14%), $R_2 + CoCl_2$ (16%) and Vit. $E + CoCl_2$ (10%) when compared to control. However, there was a significant ($p < 0.05$) decrease in the cardiac and renal activity of GPx in $R_1 + CoCl_2$ (21%, 9%), $R_2 + CoCl_2$ (20%, 16%) and Vit. E + CoCl (24%, 16%) treated rats when compared to $CoCl_2$ only. Meanwhile, there was a significant ($p < 0.05$) increase in the renal GPx activity by 22% and 11% in $CoCl_2$ only and $R_1 + CoCl_2$ treated rats respectively when compared to the control. In (Fig. 2a), there was a significant ($p < 0.05$) decrease in the cardiac activity of glutathione S-transferase by 38%, 35% and 14.5% in $CoCl_2$ only, $R_1 + CoCl_2$ and Vit. $E + CoCl_2$ treated rats respectively when compared to the control. Meanwhile, a significant ($p < 0.05$) increase in the cardiac activity of glutathione S-transferase was observed in $R_2 + CoCl_2$ (50%) and Vit. $E + CoCl_2$ (37%) treated rats when compared to $CoCl_2$ only. A significant ($p < 0.05$) decrease in the renal glutathione S-transferase activity was seen in $R_1 + CoCl_2$ (35%), $R_2 + CoCl_2$ (39%) and Vit. $E + CoCl_2$ (37%) treated rats when compared to $CoCl_2$ only; and a significant ($p < 0.05$) increase in $CoCl_2$ only (74%) and $R_1 + CoCl_2$ (13%) relative to the control (Fig. 2a).

There was a significant ($p < 0.05$) decrease in the cardiac and renal level of reduced glutathione in $CoCl_2$ only (15% and 17%) and $R_1 + CoCl_2$ (13% and 7%) when compared to control (Fig. 2b). However, a significant ($p < 0.05$) increase in the cardiac and renal level of reduced glutathione was observed in $R_2 + CoCl_2$ (13% and 19%) and Vit. $E + CoCl_2$ (16% and 19%) treated rats when compared to $CoCl_2$ only, and a significant ($p < 0.05$) increase in the renal level of reduced glutathione was noticed in $R_1 + CoCl_2$ (13%) relative to $CoCl_2$ only (Fig. 2b).

Results from (Fig. 3) showed a significant ($p < 0.05$) decrease in the serum nitric oxide level in $CoCl_2$ only (55%) and $R_1 + CoCl_2$ (32%) treated rats while significant ($p < 0.05$) increase with $R_2 + CoCl_2$ (72%) relative to control was observed. However, a significant ($p < 0.05$) increase in the level of serum nitric oxide was observed in $R_1 + CoCl_2$ (50%), $R_2 + CoCl_2$ (278%) and Vit. $E + CoCl_2$ (121%) treated rats when compared to $CoCl_2$ only.

There was coagulative necrosis of cardiomyocytes in rats treated with $CoCl_2$ only, interestingly rats in the control group, as well as those treated with rutin and vitamin E, showed no visible lesion (Fig. 4). Furthermore, in the kidney tissue, Coagulative necrosis and sloughing of the tubular epithelium were seen in the $CoCl_2$ only treated group.

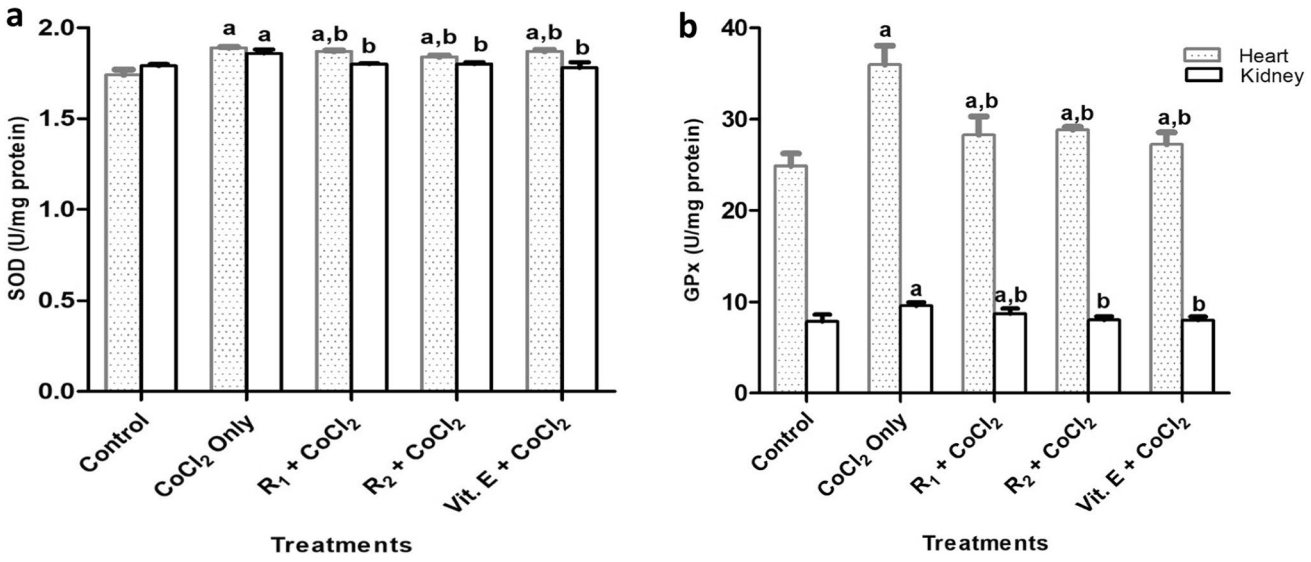

Fig. 1 Effect of Rutin and Vitamin E on the cardiac and renal activity of superoxide dismutase and glutathione peroxidase in cobalt chloride toxicity. Values are expressed in mean ± SD. Superscript (**a**) is indicative of significant value when compare to control ($p < 0.05$), while superscript (**b**) is indicative of significant value when compare to $CoCl_2$ only ($p < 0.05$)$CoCl_2$-Cobalt chloride (300 ppm), R_1-Rutin (100 mg/kg), R_2-Rutin (200 mg/kg),Vit. E- Vitamin E (50 mg/kg)

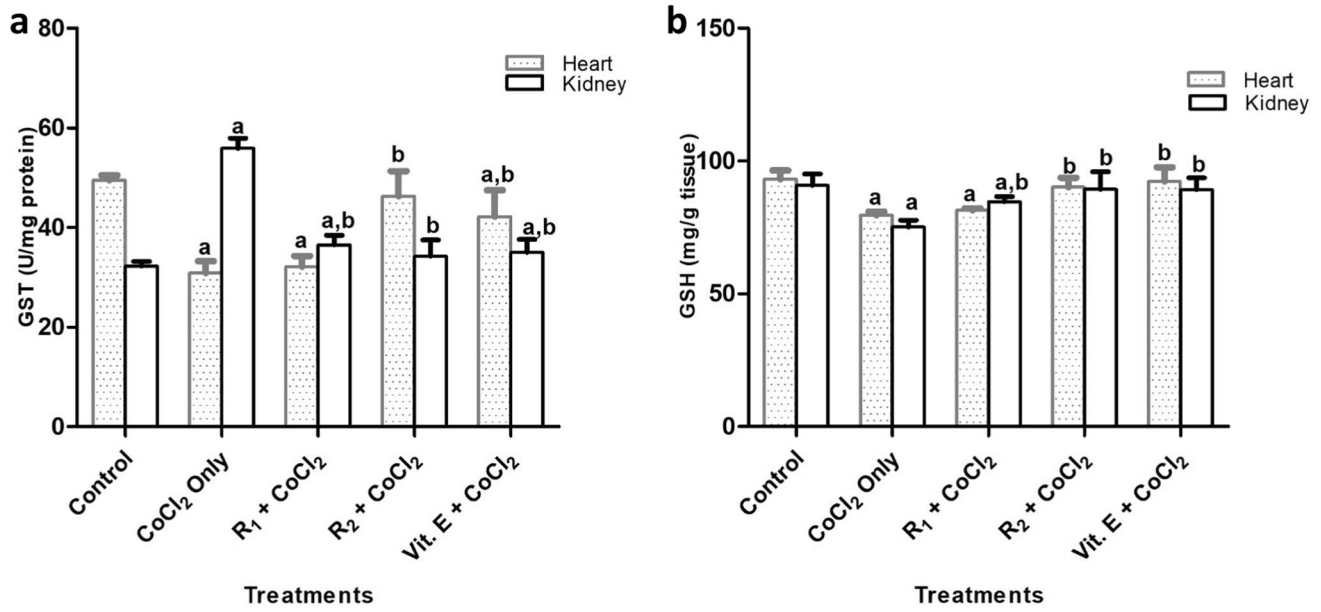

Fig. 2 Effect of Rutin and Vitamin E on the cardiac and renal level of glutathione S-transferase and reduced glutathione (GSH) in cobalt chloride toxicity. Superscript (**a**) is indicative of significant value when compare to control ($p < 0.05$), while superscript (**b**) is indicative of significant value when compare to $CoCl_2$ only ($p < 0.05$)$CoCl_2$-Cobalt chloride (300 ppm), R_1-Rutin (100 mg/kg), R_2-Rutin (200 mg/kg),Vit. E-Vitamin E (50 mg/kg)

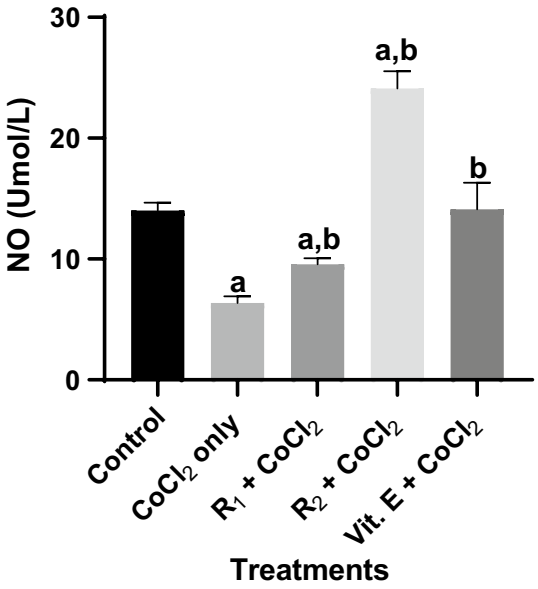

Fig. 3 Effect of Rutin and Vitamin E on the serum level of nitric oxide in cobalt chloride toxicity. Values are expressed in mean ± SD. Superscript (**a**) is indicative of significant value when compare to control ($p < 0.05$), while superscript (**b**) is indicative of significant value when compare to $CoCl_2$ only ($p < 0.05$)$CoCl_2$-Cobalt chloride (300 ppm), R_1-Rutin (100 mg/kg), R_2-Rutin (200 mg/kg),Vit. E- Vitamin E (50 mg/kg)

However, rats in the control group with those treated with $R_2 + CoCl_2$ showed no visible lesion while some denuded tubules and tubules lined by flattened epithelium filled with red blood cells were evident in $R_1 + CoCl_2$ treated rats. With rats treated with Vit. E + $CoCl_2$ some casts within renal tubules were observed (Fig. 5). A siimmunopositivity of cardiac troponin was high in rats exposed to $CoCl_2$ only while control rats and those treated with rutin and vitamin E have mild immunopositivity of cardiac troponin (Fig. 6). Mineralocorticoid receptor (MCR) is a vital receptor of note in hypertension studies. In this present research, higher expressions of MCR were recorded in $CoCl_2$ exposed rats (Fig. 7). However, there was a reduction in the expressions of MCR in the control group as well as rats treated with Rutin and Vitamin E. Lastly in Fig. 8, renal nuclear factor kappa beta (NF-κB) was assessed in this study to explore its possible involvement in $CoCl_2$ toxicity pathway. Higher immunopositivity of renal NF-κB was observed in $CoCl_2$ only treated rats in comparison to the other groups. Interestingly, concurrent administration of rutin or vitamin E resulted in a reduction in the immunopositivity of NF-κB when compared to $CoCl_2$ only treated rats (Fig. 8).

Discussion

Predominantly, previous research finding has reported that chronic exposure to cobalt could results in its accumulation in the liver, pancreas, kidneys and heart, with a time-dependent manner [1]. Supplementation with rutin and vitamin E has demonstrated in vivo antioxidant, anti-apoptotic, anti-inflammatory, and anti-autophagic characteristics and

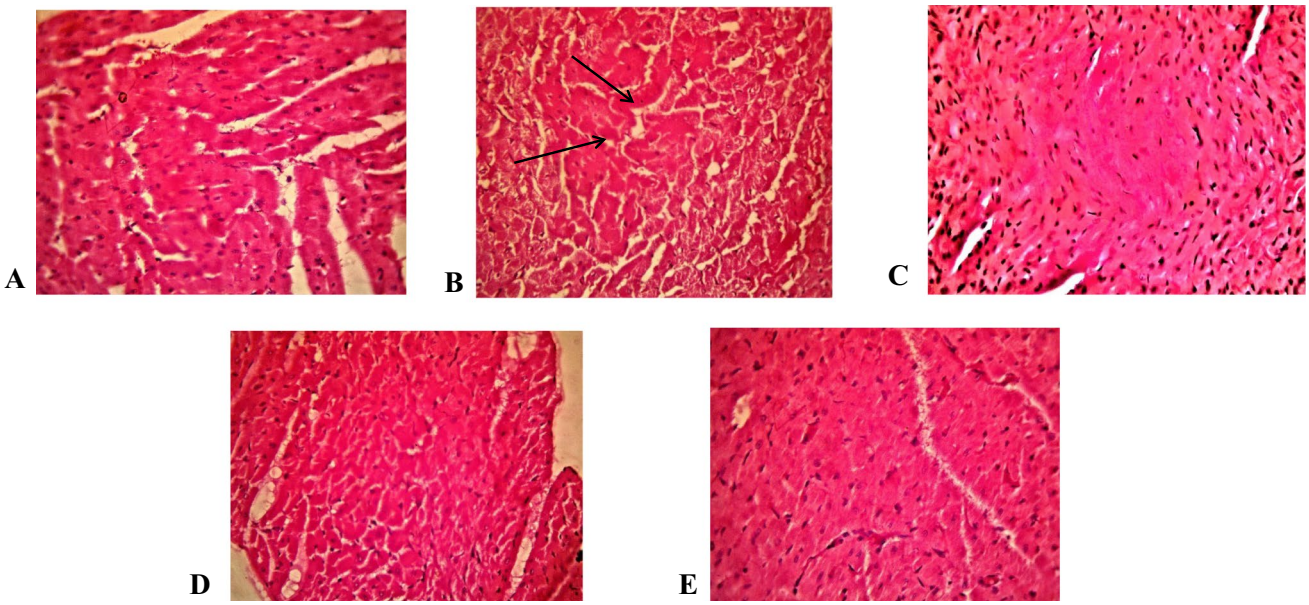

Fig. 4 Photomicrograph of the Heart showing the Effect of Rutin and Vitamin E in Cobalt chloride cobalt chloride toxicity. **A**(control), **C**(R_1+CoCl_2), **D**(R_2+CoCl_2) and **E**(Vit. E+$CoCl_2$) shows no visible lesion while **B**($CoCl_2$) shows coagulative necrosis of cardiomyocytes (arrow). Plates are stained with H and E stains and viewed with X 400 objectives

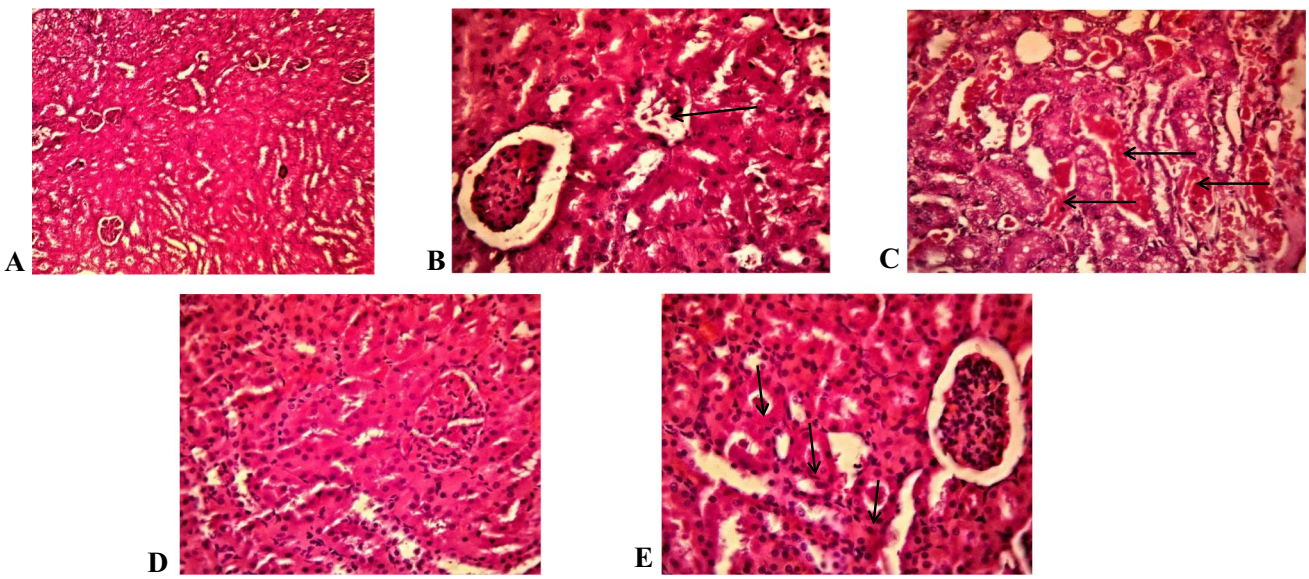

Fig. 5 Photomicrograph of the Kidney showing the Effect of Rutin and Vitamin E in Cobalt chloride cobalt chloride toxicity. A (control) and D (R_2+CoCl_2) shows no visible lesion, B($CoCl_2$)-Coagulative necrosis and sloughing of tubular epithelium (arrow), C (R_1+CoCl_2)-shows denuded tubules and tubules lined by flattened epithelium filled with red blood cells (arrow), and E (Vit. E+$CoCl_2$) shows some casts within renal tubules was observed (arrow). Plates are stained with H and E stains and viewed with X 100 for A, X 400 objectives for B, C, D and E

has been used to ameliorate nephrotoxicity induced by gentamicin in a rat model [29]. Occupational exposure to cobalt occurs in the hard metal industry (tool production, grinding, etc.) and in industries such as coal mining, metal mining, smelting, and refining, cobalt dye painting, and orthopedic implants. Animals could also be exposed to cobalt as trace element.

The significant decrease in the blood pressure observed in rats co-treated with rutin and vitamin E might be attributed to their inherent antioxidant property. This result is similar

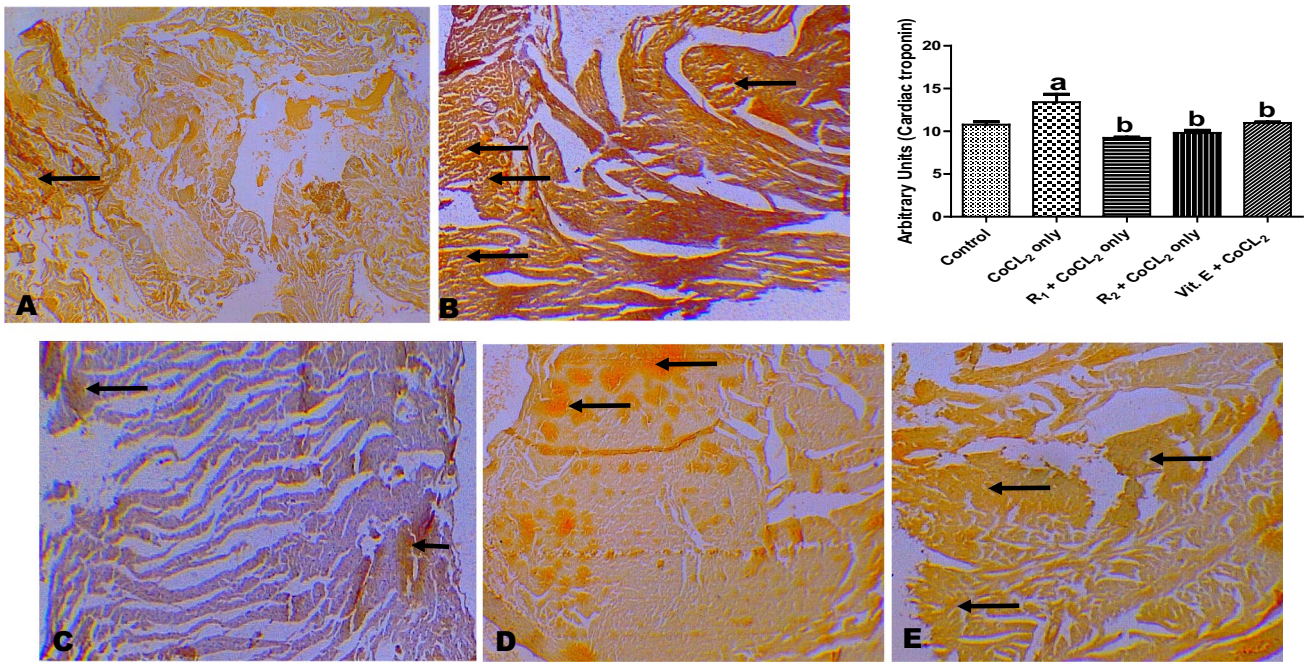

Fig. 6 The immunohistochemistry of cardiac troponin cobalt chloride toxicity. **A** (Control), **B** (Cobalt chloride; $CoCl_2$ 300 ppm), **C** ($CoCl_2$ 300 ppm + Rutin 100 mg/kg), **D** ($CoCl_2$ 300 ppm + Rutin 200 mg/kg), and **E** ($CoCl_2$ 300 ppm + Vitamin E 50 mg/kg). Slides stained with high definition Heamtoxylin. Magnification at X 100

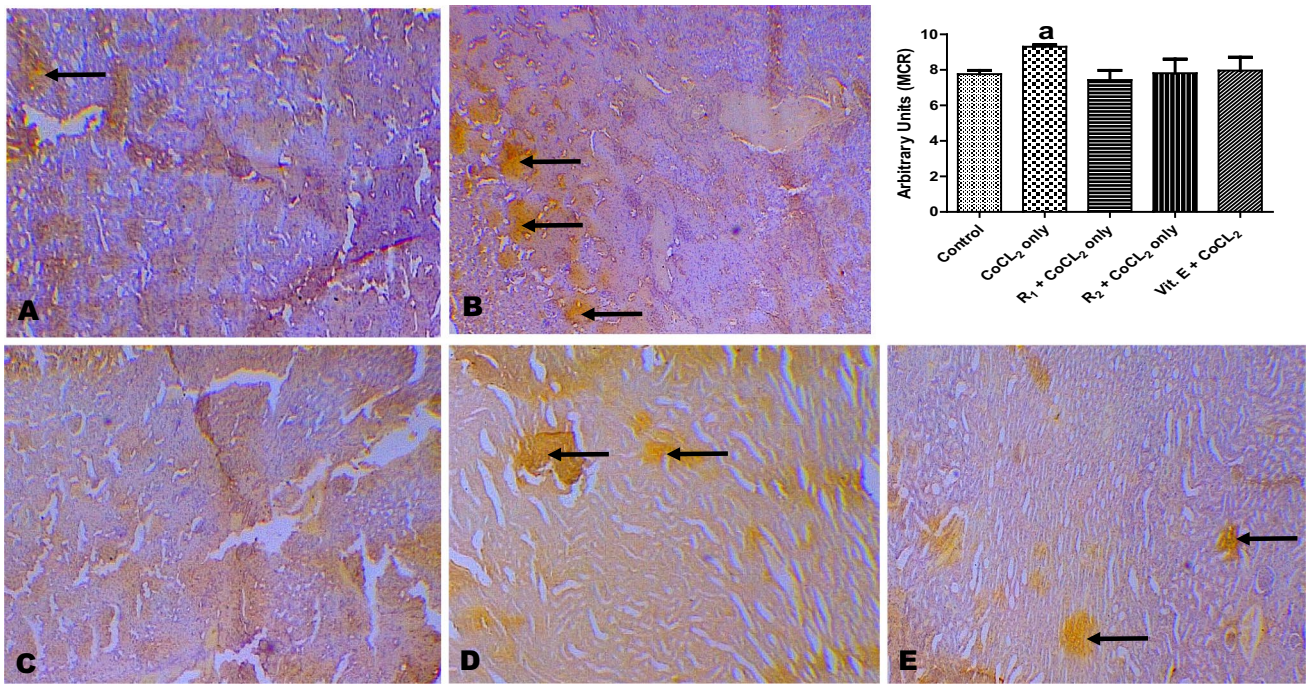

Fig. 7 The immunohistochemistry of renal mineralocorticoid receptor cobalt chloride toxicity. **A** (Control), **B** (Cobalt chloride; $CoCl_2$ 300 ppm), **C** ($CoCl_2$ 300 ppm + Rutin 100 mg/kg), **D** ($CoCl_2$ 300 ppm + Rutin 200 mg/kg), and **E** ($CoCl_2$ 300 ppm + Vitamin E 50 mg/kg). Slides stained with high definition Heamtoxylin. Magnification at X 100

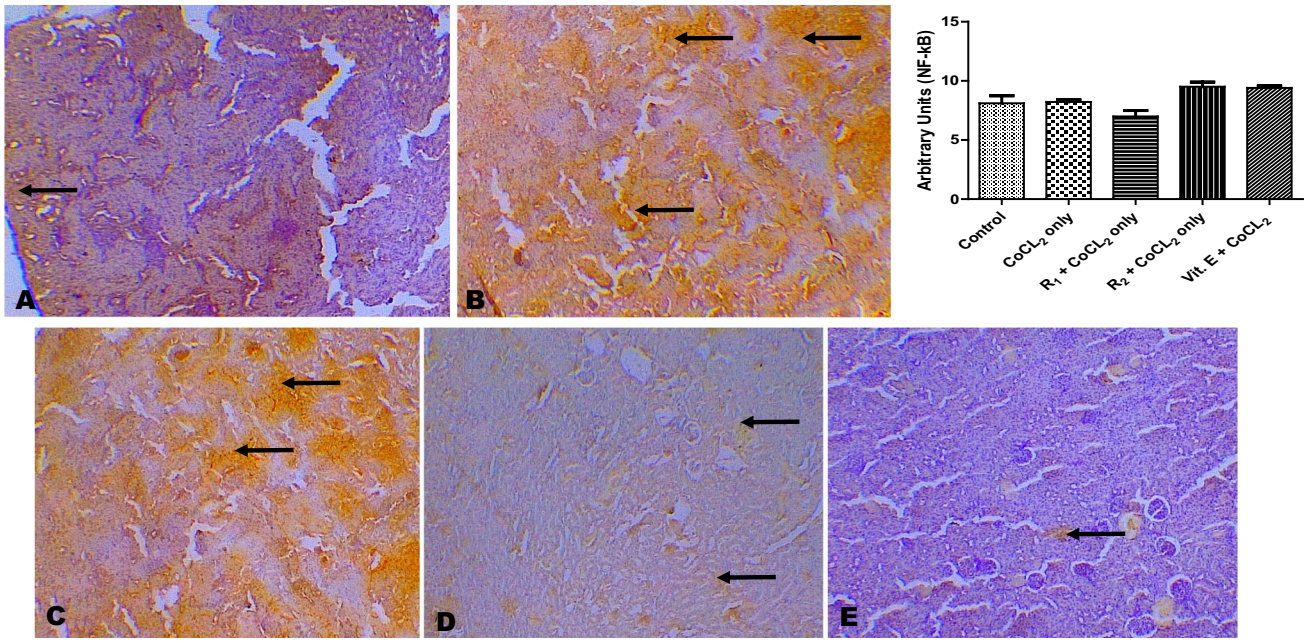

Fig. 8 The immunohistochemistry of renal nuclear factor kappa beta (NF-κB) on cobalt chloride toxicity. **A** (Control), **B** (Cobalt chloride; $CoCl_2$ 300 ppm), **C** ($CoCl_2$ 300 ppm + Rutin 100 mg/kg), **D** ($CoCl_2$ 300 ppm + Rutin 200 mg/kg), and **E** ($CoCl_2$ 300 ppm + Vitamin E 50 mg/kg). Slides stained with high definition Heamtoxylin. Magnification at X 100

to previous reports in our laboratory which emphasize the ability of $CoCl_2$ to induce hypertension and the ability of natural antioxidants to attenuate its effects [18]. Also, $CoCl_2$ treatment causes a decrease in serum nitric oxide levels relative to the control. However, co-administration with rutin and vitamin E results in a significant increase in the serum nitric oxide level. A decrease in the bioavailability of nitric oxide levels can result in severe impairment to the intrinsic vasodilatory properties specifically to the arteriolar vascular beds, intensifies systemic vascular resistance, and increases blood pressure above the normal physiological range [18].

The deleterious influences of $CoCl_2$ on the heart and kidney tissue could be explained through the promotion of oxidative injury. Co (II) alters the cellular redox chemistry where it reacts in a Fenton-type reaction, mediating the excess production of ROS. Cobalt-chloride is associated with increased reactive oxygen species production leading to cellular impairment and apoptosis in the biological systems [30]. In this study, exposure to cobalt chloride significantly increases the cardiac and renal level of hydrogen peroxide, studies have shown that cobalt in a phosphate buffer system is capable of reacting with H_2O_2, particularly when glutathione or histidine is present, to generate both superoxide and hydroxyl radicals, which is capable of altering DNA nucleotide's structure [30]. Meanwhile, co-administration with rutin and vitamin E offers protection and leads to a significant decrease in the level of hydrogen peroxide when compared to cobalt chloride only. In this study, the level of malondialdehyde (MDA) in the cardiac and renal tissues of rats treated with cobalt chloride increases significantly when compared to the control. However, a significant decrease was observed upon co-administration with rutin and vitamin E, this finding is similar to the results obtained by Kandemir et al. [31]. Increased MDA level suggests an increased lipid peroxidation process on the cell membrane. Lipid peroxidation decreases cell membrane fluidity and increases fragility, and in turn, disturbs anchored receptors and enzyme functions on the cell membrane, alters the cell membrane permeability, and ultimately leads to irregularities in calcium ions entry. This disrupts the endoplasmic reticulum, destroys many enzymes and eventually results in cell death [13].

Under normal physiological conditions intracellular antioxidant enzymes, including superoxide dismutase (SOD), glutathione-S-transferase (GST), and glutathione peroxidase (GPx), scavenge reactive oxygen species and thus plays a vital role as an antioxidative agent against cellular damage [32]. From this study, there was a significant increase in the cardiac and renal activity of SOD and GPx upon administration of $CoCl_2$. However, co-administration with rutin and vitamin E significantly reduces these enzyme activities in the cardiac and renal tissues when compared to $CoCl_2$ only, this might be attributed to the ability of rutin and vitamin E to act as an exogenous source of antioxidants thereby buffering endogenous antioxidant effect. Enhanced enzyme activity seen in rats exposed to only $CoCl_2$ can be associated with the adaptive response mechanism inherent within

the rats responding to high doses of cobalt chloride in this acute study resulting in a boost of intracellular antioxidant enzyme activity [33].

Glutathione S-transferase exerts its protective role against free radical-induced cellular injury by catalyzing lipid peroxide decomposition [34]. The overwhelming effect of free radicals led to a significant decrease in the cardiac activity of GST in $CoCl_2$-treated rats and rutin (100 mg/kg) co-treated rats when compared to the control. However, a significant increase in cardiac GST activity was seen in rutin (200 mg/kg) and vitamin E administration when compared to $CoCl_2$ only, further supporting their inherent antioxidant property [35]. In renal tissue, glutathione-S-transferase activity increases significantly in $CoCl_2$-treated rats only, and groups co-administered with rutin and vitamin E when compared to control, this might be attributed to the adaptive response mechanism. Interestingly, despite enhancing the renal activity of GST, treatment with rutin and vitamins results in the activity of this enzyme being lower in the treated rats compared to rats treated with $CoCl_2$ only.

Depletion of GSH leads to oxidative injury due to the impairment in scavenging ROS [36]. In this study, $CoCl_2$ treatment leads to a significant decrease in the cardiac and renal GSH level in $CoCl_2$ only and co-treatment with rutin at 100 mg/kg when compared to control. However, co-treatment with a higher dose of rutin (200 mg/kg) and vitamin E significantly increases the cardiac and renal levels of GSH. Estimation of GSH levels helps in understanding the severity of oxidative damage induced by $CoCl_2$. Many metals, including cobalt, due to their electron-sharing properties, form covalent bonds with sulfhydryl groups such as in GSH [37], with the potential of displacing divalent cations present in the antioxidant marker active centre. Thus, cobalt can reduce glutathione levels or inactivate antioxidant enzymes, resulting in increased intracellular ROS concentrations, signifying ROS-mediated injury. Rutin and vitamin E being able to reverse $CoCl_2$ toxicity is dependent on it activating endogenous antioxidant enzymes (SOD, CAT, GPx, GSH) as well as scavenging free radicals in cardiac and renal cells hence protecting them from undergoing damage [35, 38].

The histopathological assessment of the heart of the rat administered with cobalt chloride shows coagulative necrosis of the cardiomyocytes. However, no visible lesion was observed in other groups. This study is consistent with other report who observed that high-dose cobalt chloride caused specific changes in the ultrastructure of cardiac myocytes including vacuolar degeneration, mitochondrial swelling and reduction in mitochondrial cristae [39]. Also, the kidney structure shows coagulative necrosis and sloughing of tubular epithelium in rats administered with cobalt chloride (300 mg/kg) only, Rats treated with $CoCl_2$ and rutin (100 mg/kg) show denuded tubules and tubules lined by flattened epithelium filled with red blood cells while Vit. E + $CoCl_2$ treated rats show some casts within renal tubules. The study of Akinrinde et al. [1] shows that renal tissues from rats exposed to cobalt chloride also had necrotic and inflammatory lesions, with the histological indication of loss of renal tubular cells and cardiomyocytes during exposure correlating with the biochemical assessment of oxidative processes and apoptosis. However, treatment with 200 mg rutin prevented the aforementioned histopathological alterations induced by $CoCl_2$.

Cardiac troponin I (cTnI) and T (cTnT) are proteins specific to the heart forming a complex that binds to thin filaments within the cardiomyocyte sarcomere and conjoin with cardiac troponin C (cTnC) to produce muscular contraction dependent on calcium [40]. They are sensitive biomarkers of myocardial cell damage [41] and also a diagnostic marker of cardiac damage [42]. In cobalt chloride-only treated rats, severe expression of cardiac troponins was observed when compared to the control, rutin and vitamin E treated groups, a low expression of cardiac troponins was observed establishing the anti-hypertensive and regulatory effect of rutin and vitamin E on cardiac troponin, thus regulating the blood pressure.

The mineralocorticoid receptor (MCR) is known to regulate blood pressure and control renal sodium handling in response to aldosterone. Other than the kidney, MCR is also expressed in the heart, adipose tissue, and vasculature [43]. Severe expression of mineralocorticoid receptors was observed in the kidneys of rats treated with cobalt chloride only via immunohistochemical staining. However, MCR expression was mild in rutin and vitamin E-treated rats when compared to the control, establishing the ameliorative effect of rutin and vitamin E in rats exposed to cobalt chloride.

Nuclear factor-kappa beta (NF-kb), a pro-inflammatory, redox-sensitive nuclear transcription factor and a possible target for reactive oxygen species in vascular and endothelial smooth muscle cells has been broadly involved in a hypertensive rat model, and its activation has been related to inflammation of the blood vessels [30, 44]. The immunohistochemical evaluation showed severe renal NF-kb expression in experimental rats treated with cobalt chloride only relative to control, rutin and vitamin E-treated rats. This finding is similar to the study of Ajibade et al. [45], who observed that increased expression of NF-kb in rats exposed to cobalt chloride may have contributed to the structure alteration and function of resistance vascular beds.

Conclusion

From this study, we confirmed the ability of rutin and vitamin E to attenuate cobalt chloride-induced cardiac and renal toxicity in a dose-dependent manner. Rutin and vitamin E possess the ability to inhibit inflammation and nitrosative/

oxidative stress in the kidneys and tissue. They did not possess any adverse effects on normal rats, showing that they should be considered as potential agents to mitigate or prevent nephrotoxicity and cardiotoxicity.

Acknowledgements The authors acknowledge the technical assistance of Mr. Olalekan Agboola and Mrs. Adedayo Olawoyin of the Department of Veterinary Physiology and Biochemistry, Faculty of Veterinary University of Ibadan, Nigeria.

Authors contribution ERA, OVA, and AAO designed the experiment. ERA, OVA, TOA, OOE, AVA ran the biochemical assay. Histopathology was performed and interpreted by MOA and OOI. ERA, OVA, EOA, and AAO drafted the manuscript. AAO, TOO, OEO, ABS, AAA, supervised the study. SMN, EV, OOO, and MAY proofread and approved the manuscript for submission. The authors confirm that no paper mill and artificial intelligence was used.

Declarations

Conflict of interest Authors state no conflict of interest.

Ethical approval Research involving animals complied with all guidelines for animal protection and welfare were followed strictly (NIH Publications No. 8023, revised 1978).

Informed consent Informed consent was obtained from all individuals included in this study.

References

1. Akinrinde AS, Oyagbemi AA, Omobowale TO, Asenuga ER, Ajibade TO (2016) Alterations in blood pressure, antioxidant status and caspase 8 expression in cobalt chloride-induced cardiorenal dysfunction are reversed by *Ocimum gratissimum* and gallic acid in Wistar rats. J Trace Elem Med Biol 36:27–37
2. Zhang N, Yang S, Yang J, Deng Y, Li S, Li N et al (2020) Association between metal cobalt exposure and the risk of congenital heart defect occurrence in offspring: a multi-hospital case-control study. Environ Health Prev Med 25(1):38. https://doi.org/10.1186/s12199-020-00877-2
3. Tripathi VK, Subramaniyan SA, Hwang I (2019) Molecular and cellular response of co-cultured cells toward cobalt chloride ($CoCl_2$)-induced hypoxia. ACS Omega 4(25):20882–20893
4. Alexa T, Luca A, Dondas A, Bohotin CR (2015) Preconditioning with cobalt chloride modifies pain perception in mice. Exp Ther Med 4:1465–1469
5. He C, Gao M, He T, Xing F (2025) Association of cobalt exposure with all-cause and cardiovascular mortality in U.S. adults. BMC Public Health 25(1):1757. https://doi.org/10.1186/s12889-025-22753-w
6. Cheng T, Yu D, Li G, Chen X, Zhou L, Wen Z (2024) Association between exposure to urinary metal and all-cause and cardiovascular mortality in US adults. PLoS ONE 19(12):e0316045. https://doi.org/10.1371/journal.pone.0316045
7. Martinez-Morata I, Schilling K, Glabonjat RA, Domingo-Relloso A, Mayer M, McGraw KE et al (2024) Association of urinary metals with cardiovascular disease incidence and all-cause mortality in the multi-ethnic study of atherosclerosis (MESA). Circulation 150(10):758–769. https://doi.org/10.1161/CIRCULATIONAHA.124.069414
8. Brennan PC, Peterson SM, O'Byrne TJ, Laporta ML, Wyles CC, Jannetto PJ et al (2024) Blood metal concentrations and cardiac structure and function in total joint arthroplasty patients. World J Orthop 15(8):773–782. https://doi.org/10.5312/wjo.v15.i8.773
9. Yim G, Wang Y, Howe CG, Romano ME (2022) Exposure to metal mixtures in association with cardiovascular risk factors and outcomes: a scoping review. Toxics 10(3):116. https://doi.org/10.3390/toxics10030116
10. Wu K, Chen Y, Huang W (2025) Combined Molecular Toxicity Mechanism of Heavy Metals Mixtures. Toxic Assess Comb Chem Environ 14:125–172
11. Kurutas EB (2015) The importance of antioxidants which play the role in cellular response against oxidative/nitrosative stress: current state. Nutr J 5:1–22
12. Halliwell B (2024) Understanding mechanisms of antioxidant action in health and disease. Nat Rev Mol Cell Biol 25(1):13–33
13. Forouzanfar F, Sahranavard T, Tsatsakis A, Iranshahi M, Rezaee R (2025) Rutin: a pain-relieving flavonoid. Inflammopharmacol 33(3):1289–1301
14. Malekpour M, Ebrahiminezhad A, Karimi Z, Saadi MI, Berenjian A (2025) Current strategies for rutin nano-formulation; a promising bioactive compound with increased efficacy. Bioprocess Biosyst Eng 48(6):877–898
15. Fagan MM, Harris P, Adams A, Pazdro R, Krotky A, Call J, Duberstein KJ (2020) Form of vitamin E supplementation affects oxidative and inflammatory response in exercising horses. J Equine Vet Sci 91:103103
16. Ajibade TO, Ohore OM, Esan OO, Adeoye BO, Ake AS, Adetona MO et al (2025) Silymarin attenuates cobalt chloride-induced redox imbalance and cardio-renal dysfunctions in rats. Drug Chem Toxicol. https://doi.org/10.1080/01480545.2025.2499540
17. Institute of Laboratory Animal Resources (US) (1986) Committee on care, use of laboratory animals. Guide for the care and use of laboratory animals. US Department of Health and Human Services, Public Health Service, National Institutes of Health
18. Oyagbemi AA, Omobowale TO, Awoyomi OV, Ajibade TO, Falayi OO, Ogunpolu BS et al (2019) Cobalt chloride toxicity elicited hypertension and cardiac complication via induction of oxidative stress and upregulation of COX-2/Bax signaling pathway. Hum Exp Toxicol 38(5):519–532
19. Gornall AG, Bardawill CJ, David MM (1949) Determination of serum proteins by means of the biuret reaction. J Biol Chem 177(2):751–766
20. Misra HP, Fridovich I (1972) The role of superoxide anion in the autoxidation of epinephrine and a simple assay for superoxide dismutase. J Biol Chem 247(10):3170–3175
21. Oyagbemi AA, Omobowale TO, Akinrinde AS, Saba AB, Ogunpolu BS, Daramola O (2015) Lack of reversal of oxidative damage in renal tissues of lead acetate-treated rats. EnvironToxicol 30(11):1235–1243
22. Jollow DJ, Mitchell JR, Zampaglione NA, Gillette JR (1974) Bromobenzene-induced liver necrosis. Protective role of glutathione and evidence for 3, 4-bromobenzene oxide as the hepatotoxic metabolite. Pharmacology 11(3):151–169
23. Habig WH, Pabst MJ, Jakoby WB (1974) Glutathione s-transferases. The first enzymatic step in mercapturic acid formation. J Biol Chem 249(22):30–39
24. Beutler E, Duron O, Kelly BM (1963) Improved method for the determination of blood glutathione. J Lab Clin Med 61:882–888
25. Varshney R, Kale RK (1990) Effects of calmodulin antagonists on radiation-induced lipid peroxidation in microsomes. Int J Radiat Biol 58(5):733–743
26. Wolff SP (1994) Ferrous ion oxidation in presence of ferric ion indicator xylenol orange for measurement of hydroperoxides. Methods Enzymol 233:182–189

27. Olaleye SB, Adaramoye OA, Erigbali PP, Adeniyi OS (2017) Lead exposure increases oxidative stress in the gastric mucosa of HCl/ethanol-exposed rats. 13(38):5121–5126 https://doi.org/10.3748/wjg.v13.i38.5121
28. Drury RA, Wallington EA (1967) Cameron SR. Carleton's histological technique. London
29. Ozkan S, Isildar B, Neccar D, Koyuturk M (2025) Dynamic analysis of metabolic and ultrastructural changes in mesenchymal stem cells at hypoxic preconditioning and post-preconditioning stages: Cobalt chloride on the spotlight. Tissue Cell 95:102923. https://doi.org/10.1016/j.tice.2025.102923
30. Abdel-Daim MM, Khalil SR, Awad A, Abu Zeid EH, El-Aziz RA, El-Serehy HA (2020) Ethanolic extract of *Moringa oleifera* leaves influences NF-κB signaling pathway to restore kidney tissue from cobalt-mediated oxidative injury and inflammation in rats. Nutrients 12(4):1031. https://doi.org/10.3390/nu12041031
31. Kandemir FM, Ozkaraca M, Yildirim BA, Hanedan B, Kirbas A, Kilic K et al (2015) Rutin attenuates gentamicin-induced renal damage by reducing oxidative stress, inflammation, apoptosis, and autophagy in rats. Ren Fail 37(3):518–525
32. Awoyemi OV, Okotie UJ, Oyagbemi AA, Omobowale TO, Asenuga ER, Ola-Davies OE et al (2017) Cobalt chloride exposure dose-dependently induced hepatotoxicity through enhancement of cyclooxygenase-2 (COX-2)/B-cell associated protein X (BAX) signaling and genotoxicity in Wistar rats. Environ Toxicol 32(7):1899–1907
33. Akinrinde AS, Samuel ES, Adeoye BO (2024) Dose-dependent effects of cobalt chloride supplementation in a rat model of acetic acid-induced ulcerative colitis. Comp Clin Pathol 33(5):705–717
34. Keshavarzi M, Naraki K, Razavi BM, Hosseinzadeh H (2025) Ameliorative and protective effects of coenzyme Q10 against natural and chemical toxicity: a narrative review. Naunyn Schmiedebergs Arch Pharmacol. https://doi.org/10.1007/s00210-025-03992-5
35. Sharma S, Rabbani SA, Narang JK, Pottoo FH, Ali J, Kumar S et al (2020) Role of rutin nanoemulsion in ameliorating oxidative stress: pharmacokinetic and pharmacodynamics studies. Chem Phys Lipids 228:104890
36. Liu T, Sun L, Zhang Y, Wang Y, Zheng J (2022) Imbalanced GSH/ROS and sequential cell death. J Biochem Mol Toxicol 36(1):e22942
37. Van Daalen KR (2023) Environmental arsenic exposure and risk of cardiovascular disease (Doctoral dissertation)
38. Higgins MR, Izadi A, Kaviani M (2020) Antioxidants and exercise performance: with a focus on vitamin E and C supplementation. Int J Environ Res Public Health 17(22):8452
39. Liu M, Liu P, Zheng B, Liu Y, Li L, Han X et al (2022) Cardioprotective effects of alantolactone on isoproterenol-induced cardiac injury and cobalt chloride-induced cardiomyocyte injury. Int J Immunopathol Pharmacol. https://doi.org/10.1177/20587384211051993
40. Starnberg K, Friden V, Muslimovic A, Ricksten SE, Nyström S, Forsgard N, Lindahl B, Vukusic K, Sandstedt J, Dellgren G, Hammarsten O (2020) A possible mechanism behind faster clearance and higher peak concentrations of cardiac troponin I compared with troponin T in acute myocardial infarction. Clin Chem 66(2):333–341
41. Lippi G, Lavie CJ, Sanchis-Gomar F (2025) Detecting cardiac injury: the next generation of high-sensitivity cardiac troponins improving diagnostic outcomes. Clin Chem Lab Med. https://doi.org/10.1515/cclm-2025-0418
42. Oyagbemi AA, Omobowale TO, Asenuga ER, Abiola JO, Adedapo AA, Yakubu MA (2018) Kolaviron attenuated arsenic acid induced-cardiorenal dysfunction via regulation of ROS, C-reactive proteins (CRP), cardiac troponin I (CTnI) and BCL2. J Integr Complement Med 8(3):396–409
43. Bauersachs J, Lother A (2022) Mineralocorticoid receptor activation and antagonism in cardiovascular disease: cellular and molecular mechanisms. Kidney Int 12(1):19–26
44. Isik B, Suleyman B, Mammadov R, Bulut S, Yavuzer B, Altuner D et al (2025) Protective effect of cinnamon extract against cobalt-induced multiple organ damage in rats. Front Pharmacol 15:1384181. https://doi.org/10.3389/fphar.2024.1384181
45. Ajibade TO, Oyagbemi AA, Omobowale TO, Asenuga ER, Adigun KO (2017) Quercetin and vitamin C mitigate cobalt chloride-induced hypertension through reduction in oxidative stress and nuclear factor kappa beta (NF-Kb) expression in experimental rat model. Biol Trace Elem Res 175:347–359

Publisher's Note Springer Nature remains neutral with regard to jurisdictional claims in published maps and institutional affiliations.

Springer Nature or its licensor (e.g. a society or other partner) holds exclusive rights to this article under a publishing agreement with the author(s) or other rightsholder(s); author self-archiving of the accepted manuscript version of this article is solely governed by the terms of such publishing agreement and applicable law.

Authors and Affiliations

Ebunoluwa Racheal Asenuga[1] · Omolola Victoria Awoyomi[2] · Temitayo Olabisi Ajibade[3] · Oluwaseun Olanrewaju Esan[4] · Moses Olusola Adetona[6] · Taiwo Olaide Oyagbemi[2] · Adewumi Victoria Adeogun[3] · Olumayowa Olawumi Igado[5] · Ebenezer Oyedele Ajiboye[7] · Ademola Adetokunbo Oyagbemi[3] · Temidayo Olutayo Omobowale[4] · Olufunke Eunice Ola-Davies[3] · Adebowale Benard Saba[8] · Adeolu Alex Adedapo[8] · Sanah Malomile Nkadimeng[9] · Evaristus Nwulia[10] · Oluwafemi Omoniyi Oguntibeju[11] · Momoh Audu Yakubu[12]

✉ Ademola Adetokunbo Oyagbemi
ademola.oyaggemi778@gmail.com

[1] Department of Veterinary Physiology and Biochemistry, Faculty of Veterinary Medicine, University of Benin, Benin City, Nigeria

[2] Federal College of Animal Health and Production Technology, Moor Plantation, Ibadan, Oyo State, Nigeria

[3] Department of Veterinary Physiology and Biochemistry, Faculty of Veterinary Medicine, University of Ibadan, Ibadan, Oyo State, Nigeria

[4] Department of Veterinary Medicine, Faculty of Veterinary Medicine, University of Ibadan, Ibadan, Oyo State, Nigeria

[5] Neuroscience Unit, Department of Veterinary Anatomy, Faculty of Veterinary Medicine, University of Ibadan, Ibadan, Nigeria

[6] Department of Anatomy, Faculty of Basic Medical Sciences, College of Medicine, University of Ibadan, Ibadan, Oyo State, Nigeria

[7] Anatomy Unit, Faculty of Basic Medical Sciences, Ajayi Crowther University, Oyo, Nigeria

[8] Department of Veterinary Pharmacology and Toxicology, Faculty of Veterinary Medicine, University of Ibadan, Ibadan, Oyo State, Nigeria

[9] Department of Life and Consumer Sciences, Collage of Agriculture and Environmental Sciences, University of South Africa Florida Campus, Johannesburg, South Africa

[10] Department of Biomedical Sciences, Faculty of Health and Wellness Sciences, Cape Peninsula University of Technology, Western Cape, Bellville 7535, South Africa

[11] Department of Psychiatry and Behavioral Sciences, Howard University, College of Medicine, Howard University Hospital, 2041 Georgia Avenue, Washington, DC 20060, USA

[12] Department of Environmental & Interdisciplinary Sciences, College of Science, Engineering & Technology, COPHS, Texas Southern University, Houston, TX, USA